

X-ray/endodontics

Timing of X-ray

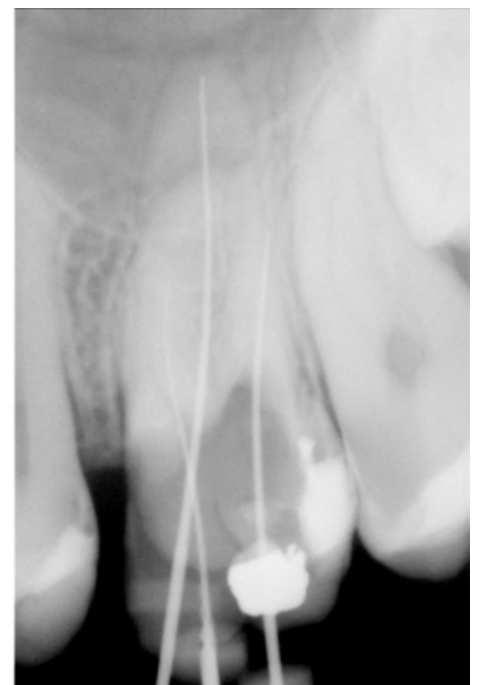
- Diagnostic
 - Coronal zone
 - Periapical zone
- During the endodontic treatment
- Follow up radiographs

Diagnostic X-rays

- Coronal zone X-ray
 - Preventive X-ray
 - Bite wing technique
- Periapical X-ray
 - Bisecting angle technique
 - Paralleling technique
 - Eccentric periapical X-ray

X-ray During Endodontic Treatment

- **Preoperative periapical radiograph**
 - quality of the previous endodontic fillings
 - fractured instruments
 - perforations
- **Working length radiograph**
 - for that purpose we use a K-file or a H-file
- **Before definitive filling of the canals with the main gutta percha point at right working length**
 - we check the accuracy of the apical saddle
- **After definitive filling of the canals**
 - We check whether we were successful or not



Tooth 26 during root canal treatment

X-ray in Follow up

- Is done after 6 months, 12 months, 2 years and 4 years after the end of the treatment
- Success depends on whether the contours, width and structure of periodontal space are normal

Links

Related Articles

Bibliography

- OTT, Daniel. *Xray endo* [lecture for subject Endodontics, specialization Endodontics, LF1 Charles University]. Prague. December 2010.