

# Ventral and Dorsal Spinal Nerve Root

Contains Info about:

Ventral and dorsal spinal nerve root, dorsal root ganglion, draw general structure of the spinal nerve and its branches, autonomic fibers of spinal nerves

The peripheral nervous system (PNS) comprises spinal nerves and cranial nerves, totaling 12 pairs of cranial nerves. Spinal nerves, derived from the spinal cord, consist of 31 pairs in total:

- Cervical: 8 pairs
- Thoracic: 12 pairs
- Lumbar: 5 pairs
- Sacral: 5 pairs
- Coccygeal: 1 pair

This division of spinal nerves corresponds to the different regions of the spinal cord and reflects their specific roles in transmitting sensory and motor information to and from the body.

Peripheral nerves can carry four or five different types of fibers, each serving distinct functions:

1. **Somatomotor (Efferent):** These fibers transmit signals to the striated musculature of the body wall and limbs, regulating movement and tension in skeletal muscles. They are responsible for voluntary movements.
2. **Somatosensory (Afferent):** Sensory fibers conveying information from the skin and musculature of the body wall and limbs. They receive input from mechanoreceptors, exteroceptors, proprioceptors, and thermoreceptors on the body surface (skin).
3. **Visceromotor (Efferent) - Autonomic:** Participating in the regulation of activity in smooth muscles, myocardial cells, glands, and blood vessels. These fibers are involved in autonomic functions.
4. **Viscerosensory (Afferent):** Sensory fibers transmitting information from the viscera (inner organs). They convey data from baroreceptors, chemoreceptors, and receptors within internal organs, detecting factors such as wall tension, pain, and chemical stimuli.
5. **Special Sensory:** These fibers are responsible for conveying specific sensory information from specialized organs, such as the ears and eyes. They play a crucial role in functions like hearing and vision.

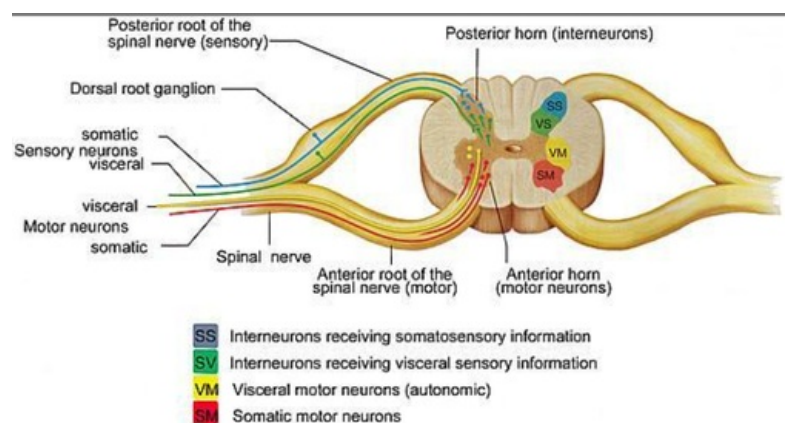
The grey matter of the spinal cord is composed of four parts, each giving rise to different fibers that form the peripheral nervous system (PNS):

1. **Anterior Horn:** This region contains the cell bodies of somatomotor neurons, which are responsible for transmitting efferent signals to skeletal muscles, regulating voluntary movement.
2. **Lateral Horn:** Here, you find the cell bodies of visceromotor neurons, part of the autonomic nervous system. These neurons regulate involuntary functions of smooth muscles, myocardial cells, glands, and blood vessels.
3. **Intermediate Zone:** This area houses the cell bodies of viscerosensory neurons, which receive afferent signals from internal organs. They convey information regarding factors such as wall tension, pain, and chemical stimuli.
4. **Dorsal Horn:** In this part, you'll find the cell bodies of somatosensory neurons, responsible for transmitting afferent signals from the skin and musculature of the body wall and limbs. They receive input from various sensory receptors, including mechanoreceptors, exteroceptors, proprioceptors, and thermoreceptors.

From the grey matter, these fibers exit through the intervertebral foramen, forming two roots of the spinal nerve. This organizational structure allows for the transmission of both efferent and afferent signals between the spinal cord and the rest of the body via the peripheral nervous system.

The spinal nerve roots play a crucial role in transmitting signals between the spinal cord and the peripheral nervous system. Here's how they function:

1. **Anterior Root:** This root primarily carries motor fibers, including both visceromotor and somatomotor fibers. These fibers are responsible for transmitting efferent signals from the spinal cord to various target tissues, including skeletal muscles and visceral organs, enabling voluntary and involuntary movements.
2. **Posterior Root (via the Dorsal Root Ganglion):** This root primarily carries sensory fibers, which include both viscerosensory and somatosensory fibers. These fibers transmit afferent signals from sensory receptors located in the skin, muscles, and internal organs back to the spinal cord, providing information about touch, temperature, pain, and the internal state of the body.



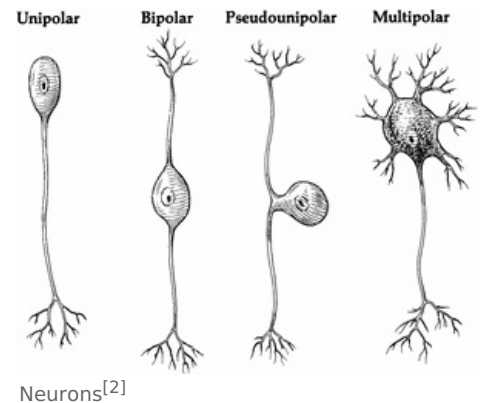
spinal nerve and its branches<sup>[1]</sup>

The dorsal root ganglion serves as a specialized structure housing the cell bodies of sensory neurons, allowing for efficient transmission of sensory information to the spinal cord. Together, the anterior and posterior roots form the spinal nerves, facilitating bidirectional communication between the central nervous system and the peripheral tissues.

## Dorsal Root Ganglion

Dorsal root ganglion (or spinal ganglion) serves as a cluster of nerve cell bodies located within the posterior root of a spinal nerve, situated in the intervertebral foramina. These ganglia primarily house the cell bodies of sensory (afferent) neurons. The axons stemming from these neurons are referred to as afferents.

In the peripheral nervous system, afferents are responsible for relaying sensory information into the central nervous system, encompassing the brain and the spinal cord. Notably, the neurons found in the dorsal root ganglia are of the pseudo-unipolar type. This classification signifies that they possess a single axon that branches into two processes, acting as both a dendrite and an axon.



## Autonomic fibers of spinal nerves

The autonomic nervous system (ANS) is subdivided into three main divisions: the sympathetic, parasympathetic, and enteric nervous systems, each with distinct functions and distributions:

### Autonomic Sensory Fibers:

- The afferent fibers of the autonomic nervous system, which transmit sensory information from the internal organs of the body back to the central nervous system (or CNS), are not divided into parasympathetic and sympathetic fibers as the efferent fibers are.
- Instead, autonomic sensory information is conducted by viscerosensory fibers.

### Sympathetic Division:

- Efferent fibers originate from cell bodies located in the lateral horn of thoracolumbar T1 – L2 vertebrae.
- Preganglionic neurons exit the ventral horn to synapse with ganglia located laterally and near the vertebral column, known as paravertebral ganglia of the sympathetic trunk.
- The ganglia serve as collections of neuronal cell bodies.
- Dorsal roots carry sensory information into the spinal cord, while ventral roots carry efferent motor information.
- Neurons exit the ventral root and synapse with sympathetic trunk ganglia through the white ramus communicans (myelinated), then join the spinal nerve via the gray ramus communicans (unmyelinated) to supply the target organ.
- Additional distribution mechanisms include ascending/descending fibers that ascend to paravertebral ganglia of the cervical region and autonomic fibers that form splanchnic nerves, bypassing spinal nerves and innervating prevertebral ganglia.

### Parasympathetic Division:

- The parasympathetic nervous system has cranial and sacral components.
- Cranial outflow involves nerves with cell bodies in brain stems, including the oculomotor (III), facial (VII), glossopharyngeal (IX), and vagus (X) nerves.
- The sacral component arises from spinal segments S2-S4 and gives rise to pelvic splanchnic nerves.
- In the sacral region, the parasympathetic nervous system innervates muscles of the rectum, bladder wall detrusor muscle, and genital system.
- Efferent fibers originate from cell bodies in the gray matter of S2-S4 and leave through the anterior ramus (visceromotor fibers) to form pelvic splanchnic nerves.
- Afferent fibers function similarly to sympathetic fibers, with cell bodies located in either posterior root ganglia or sensory cranial ganglia.

### Enteric Nervous System:

- The enteric nervous system functions independently and regulates the gastrointestinal tract.
- It consists of a complex network of neurons and glial cells embedded in the walls of the digestive system, controlling gastrointestinal motility, secretion, and blood flow.
- The enteric nervous system can operate autonomously but also receives input from the sympathetic and parasympathetic divisions of the ANS.

1. [https://corpshuman.ca/en/Moelle\\_epi\\_en.php](https://corpshuman.ca/en/Moelle_epi_en.php)

2. <https://www.sciencedirect.com/topics/veterinary-science-and-veterinary-medicine/pseudounipolar-neuron>

