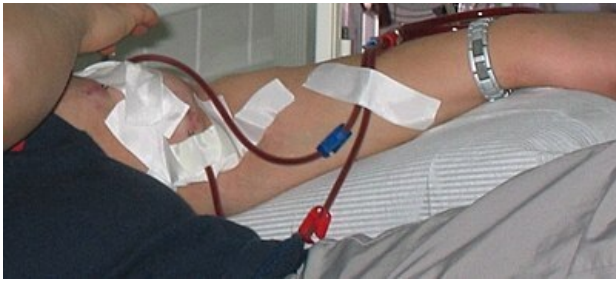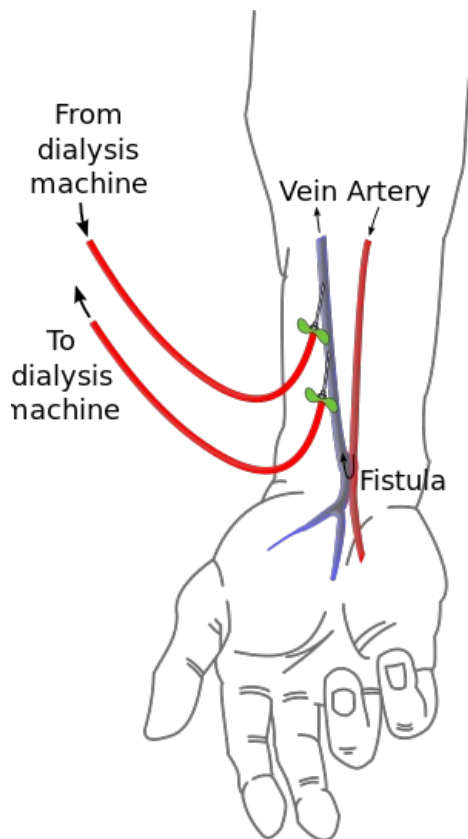


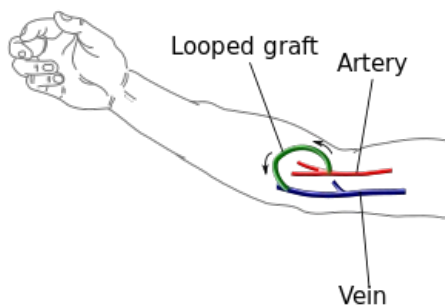
Vascular approaches for dialysis



AV shunt cannulated with dialysis needles attached to a dialysis machine



Simple radiocephalic AV shunt



AV shunt using prosthesis / autograft / allograft

An **arteriovenous shunt** (AV shunt, AV shunt, fistula, fistula) must be surgically created to connect the patient to the **dialysis machine** („artificial kidney“). It is about creating a communication between an artery and a vein. This communication then serves to insert dialysis needles that supply / discharge blood to / from the dialysis machine.^[1]

Dialysis itself falls within the expertise of a nephrologist; the creation of an AV shunt belongs to the vascular surgeon. In case of impossibility of AV short circuit or in case of urgency of the situation **special dialysis venous catheters** can be used **for dialysis** .

Indications for dialysis [2]

- **Acute/chronic renal failure.** Plasma **urea** levels above 30 mmol / l and plasma **creatinine levels** above 500 µmol/l, serum Na⁺ > 160 mmol/l or < 115 mmol/l, hyperkalemia > 6,5 mmol/l and pH < 7,1.
- **Hyperkalemia.**
- **Hyperhydration** (resistant to pharmacological treatment; associated with heart failure and pulmonary edema).
- **Uremic pericarditis.**
- **Severe metabolic acidosis.**
- **Oliguria lasting more than 3 days.**
- **Intoxication with dialysable poison.**

Type and location of vascular access

We choose the vascular approach in the following order:[3]

1. **simple AV short circuit** (vein is sutured to the artery „*end to side*“);
2. **A-V short circuit using vascular prosthesis/autograft/allograft;**
3. **permanent dialysis venous catheter.**

AV short circuit

We always try to create an AV short circuit in the **upper limb** as **distally** as **possible**. On the one hand, distal AV shorts are more comfortable for the patient, on the other hand, we reserve more proximal vessels for "worse times". We prefer a short circuit on a **non-dominant** limb and we prefer a short circuit with its own vein (before using a vascular prosthesis).

We select AV shortcuts in the following order:[3]

1. **radiocephalic junction** (AV abbreviation between a. radialis and v. cephalica, the term "Brescia-Cimino shunt" or "radiatorial fistula" is used in the foreign language literature, but it is inaccurate);
2. **ulnar-basilic junction** (AV short circuit between ulnar artery and basilica v.);
3. **radio-cephalic connector** (AV short circuit between a. radialis and v. cephalica);
4. **radio-bazilická spojka** (AV short circuit between a. radialis and v. basilica , it is necessary to perform the so-called transposition of the a. basilicae);
5. **AV shunt between a. Femoralis and v. Saphnena.**
6. **AV short circuit with the use of vascular prosthesis** (we choose this variant when it is impossible to make any type of simple connector; vascular prostheses are made of PTFE (polytetrafluoroethylene); they can be placed on the forearm, arm and lower limb; they have a shorter lifespan and higher risk of complications than simple connectors) .

In some cases, an autograft from the *saphenous vein* can be used to connect the artery and vein (*saphenous vein* allograft after varixectomy). After the AV shunt is surgically created, the part of the blood flowing through the artery begins to "escape" through the connected vein, without this blood first reaching the periphery. We are talking about the so-called " „**steal phenomenon**“". More blood is now flowing through the vein and under higher pressure → the vein is adapting to the new conditions, we are talking about „**arterialization of the vein**“ (it dilates and its wall is massive). 4-6 weeks after shunt formation, the vein is ready to insert dialysis cannulas.[4]

Kardiochirurgie.cz. *AV shunt* [online]. [cit. 2012-06-29]. <<https://www.kardiochirurgie.cz/videoanimace/av-shunt-564>>.

Dialysis venous catheters

The indications for the use of a special dialysis venous catheter are basically 2:

1. if the patient needs to be dialyzed immediately (if we cannot wait 4-6 weeks or if we have to bridge 4-6 weeks) - **temporary catheter**;
2. if it is not possible to create an AV shunt - **permanent catheter**.

These special catheters (Sheldon, Bard, Cannaud) are inserted into the central veins. Most frequently cannulated in **Internal jugular** or **v. femoralis** (rarely *v. Subclavian*).[3] Possible complications of central vein cannulation include infection, thrombosis, bleeding or stenosis.[5]

Links

Related articles

- renal function replacement

Reference

1. VANĚK, Ivan, et al. *Cardiovascular surgery*. 1. edition. Praha : Karolinum, 2003. 236 pp. ISBN 8024605236.
2. HASLETT, Christopher, et al. *Médecine interne : Principes et Pratique*. 18. edition. Paris. 2000. ISBN 0443060002.
3. QIN, Wen. Séminaire: Suppléance rénale dans l'insuffisance rénale. Grenoble, 2010.
4. VANEK, Ivan, et al. *Cardiovascular surgery*. 1. edition. Praha : Karolinum, 2003. 236 pp. ISBN 8024605236.
5. TESÁŘ, Vladimír, et al. *Nephrology*. 1. edition. Praha : Galén : Karolinum, 2003. ISBN 80-246-0671-2.

References

- GERD, Herold, et al. *Médecine interne*. 3. edition. Groupe De Boeck, 2008. 1119 pp. ISBN 978-2-8041-5686-2.
- VANEK, Ivan, et al. *Cardiovascular surgery*. 1. edition. Praha : Karolinum, 2003. 236 pp. ISBN 8024605236.