

Vascular Lacuna

English: *Vascular lacuna*
Latin: *Lacuna vasculorum*



Vascular lacuna is an anatomical structure placed behind/below the inguinal ligament. Lacuna vasorum is medially, while muscular lacuna is laterally.

Contents of lacuna vasorum (order from medial part):

- deep inguinal lymph nodes,
- femoral vein,
- femoral artery,
- femoral branch of the genitofemoral nerve.

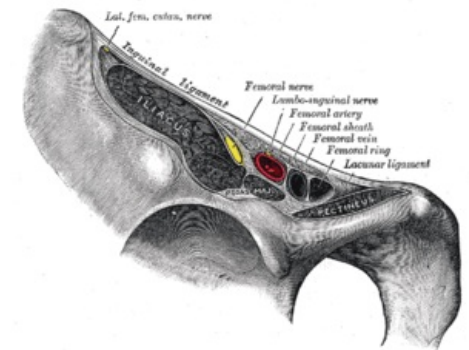
Links

Related articles

- Muscular Lacuna

Bibliography

- PETROVICKY, Pavel, et al. *Anatomie s topografií a klinickými aplikacemi : Sv. 1, Pohybové ústrojí. 1.* edition. Martin : Osveta, 2001. 463 pp. ISBN 80-8063-046-1.



Lacuna vasorum and lacuna musculorum