

Uterine tumors

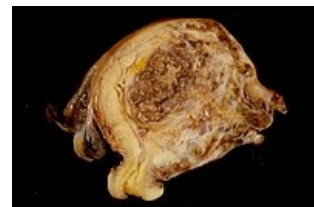
Uterine tumors can be divided into 2 large groups : cervical tumors and uterine body tumors. These groups are further divided into benign and malignant tumors.

Cervical tumors

- Benign: Endocervical polyp .
- Precancerous lesions: Cervical intraepithelial neoplasia .
- Malignant: Squamous cell carcinoma .

Tumors of the uterine body

- Benign tumors: Polyp and leiomyoma .
- Malignancies: Leiomyosarcoma, stromal sarcoma, carcinoma and carcinosarcoma .



Nádor děložního těla

Links

related articles

- Womb
- Cervix uteri
- Uterine curettage

Source

- POVÝŠIL, Ctibor and Ivo ŠTEINER, et al. *Special pathology*. 2nd edition. Prague: Galén, 2007. 430 pp. ISBN 978-807262-494-2 .
- POVÝŠIL, Ivo – ŠTEINER,. *Speciální patologie*. 2. edition. Praha : Galén, 2007. 430 pp. ISBN 978-807262-494-2.