

Uterine fibroid

Fibroids are benign monoclonal tumors of smooth muscle cells that grow from the muscle wall of intra-abdominal organs. In gynecology we talk about uterine fibroids or myoma uteri (the formation grows out of the myometrium), in the digestive tract it is a fibroid of the smooth muscle of the GIT wall.

We most often encounter fibroids in gynecology - *uterine fibroids*. Fibroids are the most common benign body in the female genital tract. The prevalence of uterine fibroids is 20-30% in women under 30 years and 50% in women over 30 years.

Uterine fibroids reach a size of 1 cm to (exceptionally) several decimetres. They can occur solitarily, sometimes they are multiple - then we talk about *myomatosis*.

Fibroids are usually **benign**. Malignant reversal of uterine fibroids is rare.

Myoma is a **hormone-dependent** tumor - it contains hormone receptors - after menopause or after treatment with GnRH, fibroid analogues regress.

Risk factors

Risk factors for uterine fibroids include genetic predisposition, hormonal and environmental influences.

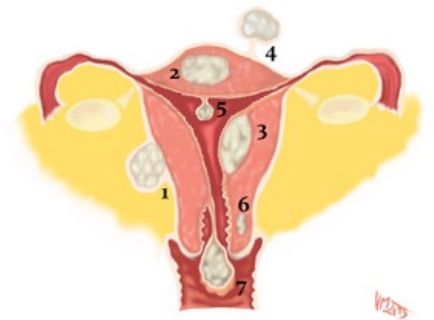
Classification

The classification of uterine fibroids is determined by their location (submucosal, intramural, subserous fibroids) and their manifestation usually depends on their location.

Clinical picture

- is determined by the size, location and number of fibroids;
- the most common symptoms - irregular uterine bleeding, pain and pressure in the lower abdomen;
- the arched fibroid compresses the endometrium - this disrupts vascularization and the wall does not separate;
- large subserous fibroids can be asymptomatic and bother with pressure or pain from necrotic changes within the fibroid;
- at fertile age, fibroids can cause infertility or sterility;
- in pregnancy, fibroids usually grow faster.

The clinical picture may be completely asymptomatic (about 1/3 of women) or with typical symptoms such as menstrual cycle disorders: *hypermenorrhea* - excessive menstrual bleeding, *menorrhagia* - prolonged menstrual bleeding, *dysmenorrhea* - painful menstrual bleeding. In fertile women we may encounter *infertility*.



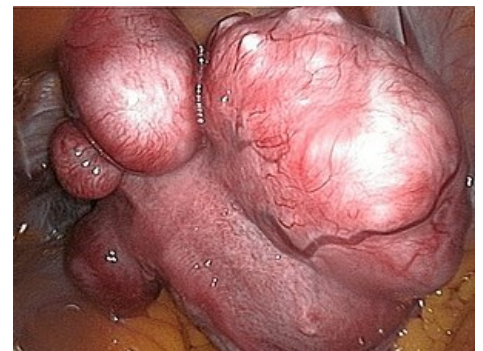Uterus myomatosus - deposition 1) subserosal, intraligamentary; 2) intramural; 3) submucosal; 4) subserous pendulum; 5) submucosal pendulum intracavitary; 6) cervical intramural; 7) cervical stalk - myoma nascent

Diagnostics

Diagnosis is most often made by gynecological examination, ultrasonography, hysteroscopy or as a surgical finding.

Therapy

Treatment of uterine fibroids depends on the symptoms. We choose a conservative solution for asymptomatic fibroids (1/3 of women need only monitoring) and for women of fertile age. If symptoms occur, surgical removal of the fibroid (hysteroscopic myomectomy, laparoscopic myomectomy, laparotomy myomectomy, laparoscopic uterine artery occlusion, fibroid embolization) or hysterectomy is necessary. In some cases, medication treatment may be indicated.



Uterus myomatosus

- In young women who are planning a pregnancy:
 - conservatively - removal of fibroids and leaving the uterus;
 - laparoscopic or hysteroscopic enucleation;
 - GnRH agonists can be used to reduce large fibroids (treatment lasts 3-5 months).
- However, fibroids most often occur in women who no longer plan parenthood:
 - if major bleeding, pain or rapid growth occurs - hysterectomy.

Links

Related articles

- Leiomyoma uteri

External links

- BENEŠ, Jiří. *Studijní materiály* [online]. [cit. 2018-01-06]. <<http://jirben2.chytrak.cz/>>.
- Děložní myomy (Gynekologická endoskopie, MUDr. Michal Mára) (http://myomy.cz/gynendoskopie/delozni_myomy.htm)

Bibliography

- MÁRA, Michal – HOLUB, Zdeněk. *Děložní myomy : Moderní diagnostika a léčba*. 1. edition. Grada, 2009. ISBN 978-80-247-1854-5.
- VOKURKA, Martin – HUGO, Jan. *Velký lékařský slovník*. 9. edition. Maxdorf, 2009. 1159 pp. ISBN 978-80-7345-202-5.
- HOLUB, Zdeněk – KUŽEL, David. *Minimálně invazivní operace v gynekologii*. 1. edition. Grada, 2007. ISBN 80-247-0834-5.