

Triangular Space

English: *Triangular space, Medial axillary space*

Latin: *Foramen omotricipitale*



The **triangular space** (**medial axillary space**, lat. *foramen omotricipitale*) is bounded by the teres minor superiorly, the teres major inferiorly, and the long head of the triceps brachii laterally.

It contains the scapular circumflex vessels (axillary artery – subscapular artery – scapular circumflex artery).

Links

Related articles

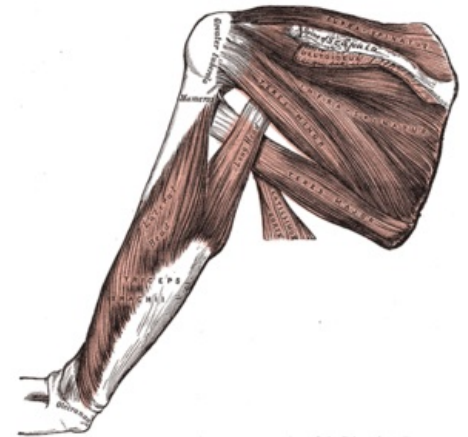
- Quadrangular Space

External links

- Photo at tufts.edu (<http://iris3.med.tufts.edu/dentgross/labguide/Shoulder4.html>)

Bibliography

- PETROVICKY, Pavel, et al. *Anatomie s topografií a klinickými aplikacemi : Sv. 1, Pohybové ústrojí*. 1. edition. Martin : Osveta, 2001. 463 pp. ISBN 80-8063-046-1.



Triangular space