



# Thrombocytopenia

**Thrombocytopenia** is a reduced amount of platelets in the blood. It is the result of an imbalance between the formation and destruction of platelets. Either few platelets are produced in the bone marrow or they are destroyed prematurely. Sometimes it can be both.

## Thrombocytopenia:



## Thrombocytopenia (details):



## Clinical picture

- **Bleeding into the skin** – petechiae with the development of purpura , larger hematomas (disproportionate to the insult / arise spontaneously).
- **Bleeding from the mucous membranes** – epistaxis , bleeding from the gums , menometrorrhagia, ( hematuria , enterorrhagia ).
- Any organ can be affected by bleeding - **worst** retinal + CNS bleeding .
- Minor injuries (puncture during blood collection) → bleeding that is often difficult to control, more serious injuries → **unstoppable bleeding**.
- Spontaneous bleeding manifestations only when thrombocytes drop below  $30 \cdot 10^9 / l$ , with a higher number of suspicions of a current disorder of their function.

## Thrombocytopenia from reduced platelet production

These are mostly **amegakaryocytic thrombocytopenia** , which means that there is a reduced amount of megakaryocytes in the bone marrow or megakaryocytes are completely absent. In this case, the attenuation is isolated / more often in the attenuation of the entire myeloid line;

- More often acquired – treatment with myelotoxic substances + ionizing radiation, viral infections, infiltration of the bone marrow by malignancy, remodeling in myeloproliferative diseases , in idiopathic ones the involvement of immunological mechanisms is assumed .

**Megakaryocytic thrombocytopenia** – in the bone marrow a normal / increased number of megakaryocytes with shape deviations

- Thrombocytopenia in megaloblastic anemia , PNH , MDS , etc.,
- Rare hereditary thrombocytopenic thrombocytopathies (eg Bernard-Soulier syndrome).

## Diagnostics

- Bone marrow examination – reduction or absence of megakaryocytes,
- Severe prognosis (hemorrhage into the CNS),
- Symptoms from the involvement of other components of hematopoiesis may prevail.

## Therapy

- Secondary thrombocytopenia – treatment of the primary disease process, removal of the causative agent,
- Immunosuppressive treatment (some cases),
- Allogeneic bone marrow transplantation ,
- Symptomatic therapy: glucocorticoids , fibrinolysis inhibitors (PAMBA), platelet transfusion (to ensure surgery).

## Thrombocytopenia from increased destruction of platelets

**Thrombocytopenia from increased destruction of platelets** is divided according to the cause into:

- **Megakaryocytic forms** with a normal/increased number of megakaryocytes in the bone marrow ,
- **Immune thrombocytopenia** – excessive breakdown of platelets in the monocyte-macrophage system,
- Other causes: large intravascular consumption in the coagulation process , losses from the organism, Thrombocytopenia from increased sequestration (redistribution of platelets outside the circulating blood - e.g. in the spleen ).

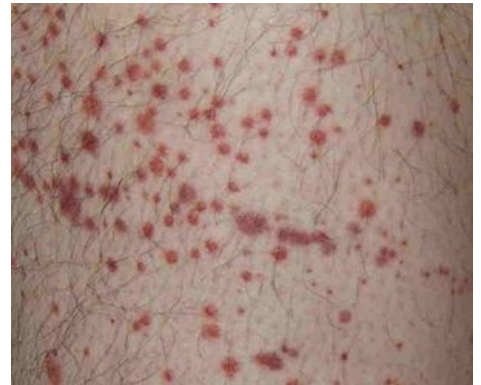

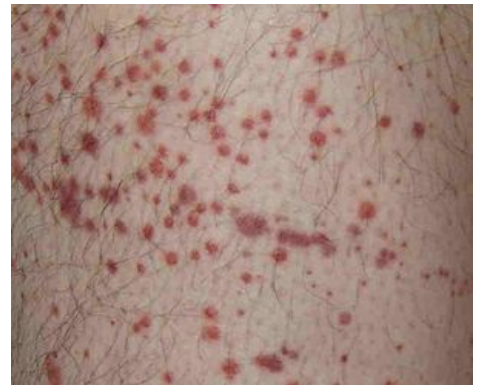Image of purpura

## Idiopathic (autoimmune) thrombocytopenic purpura (ITP, m. maculosus Werlhofi)

Idiopathic (autoimmune) thrombocytopenic purpura , (ITP) is a condition in which the rapid breakdown of platelets occurs for an unknown reason with the participation of immune mechanisms.<sup>[1]</sup> This is the most common acquired bleeding disease in childhood.<sup>[2]</sup>

## Etiopathogenesis

Autoantibodies are formed in the body (B-lymphocytes with the help of CD4+ T-lymphocytes) against platelet surface antigens, mostly against glycoprotein IIb-IIIa. The trigger is often an infection (upper respiratory tract infection, more rarely varicella, mumps, rubella, EBV infection, vaccination with a live vaccine). Platelets with bound antibodies are absorbed by macrophages and then disappear mainly in the spleen. Autoantibodies inhibit megakaryopoiesis, which results in reduced platelet production by bone marrow megakaryocytes, thrombopoietin levels are normal.<sup>[2]</sup>



Purpura – petechie

## Clinical picture

### Acute form

**It is a childhood** disease with a rapid course and often spontaneous resolution. Circulating immunocomplexes with affinity for platelets are then rapidly taken up by MMS cells . It usually follows a banal viral infection. Bleeding manifestations are present, **sudden onset** (within hours) - generalized purpura, hematomas, bleeding from mucous membranes, bleeding into organs (CNS) occur. Fortunately, the acute form is **rare**.

### Chronic form

A decrease in platelets below  $150 \times 10^9/L$  lasting more than 6 months is typical;<sup>[2]</sup> Disease of **adult age** (more often women) with insidious onset and chronic course, spontaneous remissions are rare. Principle: autoantibodies against platelet antigens → rapidly absorbed by MMS (spleen: production of antibodies + absorption and degradation of altered platelets); **Severe organ bleeding** (often fatal to the CNS) is more common .

## Diagnostics

Often, the diagnosis is clinical - it is necessary to rule out thrombocytopenia of other etiology (in childhood, marrow suppression during acute leukemia, in adulthood, MDS). We demonstrate antiplatelet antibodies. ITP can be a manifestation of SLE / B-lymphoproliferation.

## Laboratory examination

- platelet count variously reduced, in severe forms below  $10 \times 10^9/l$ ;
- other CBC parameters as well as hemostatic tests are normal;
- proliferation of megakaryocytes in the bone marrow.

## Therapy

- the basis of immunosuppression – **prednisone** 0.5–1 mg/kg (after achieving remission, we continue with the maintenance dose), or cyclophosphamide, cyclosporine;
- **splenectomy** (in patients with increased destruction of platelets in the spleen);
- anti-CD20 monoclonal antibody **rituximab** ;
- intravenous immunoglobulins in high doses (in the event of a deep drop in platelets + more pronounced bleeding manifestations with the risk of permanent consequences/life-threatening);
- in the period of more pronounced bleeding symptoms, non-specific haemostatics at the same time, in extreme cases platelet transfusions (short-term effect).

## Consumption thrombocytopenia

- Consumption of platelets in the process of intravascular microthrombotization,
- Most often with DIC ; further with TTP and HUS .

## Thrombotic thrombocytopenic purpura (TTP, Moschowitz syndrome)

It is a rarer disease compared to ITP, but has a serious prognosis.

- Fevers,
- Hemolytic anemia (microangiopathic, schistocytes in blood smear),
- Thrombocytopenia with bleeding manifestations,
- Neurological symptomatology,
- Renal impairment.

## Pathogenesis

### Idiopathic form

- In the plasma, **von Willebrand factor of high molecular weight** (as a result of the deficiency of a specific plasma metalloproteinase) with the ability to induce platelet microthrombotization.

### Hereditary form

- Mutation of the metalloproteinase gene from the ADAMTS group on chromosome 9,
- In the acquired forms, antibodies against metalloproteinases have been demonstrated,
- In order to cause a TTP attack, the participation of other agents (infection, etc.) is necessary.
- Histologically: multiple hyaline microthrombi in arterioles (central CNS + kidneys).

## Secondary thrombotic thrombocytopenic purpura

- In patients after allogeneic transplantation, in systemic diseases, generalized malignancies, after administration of certain drugs (quinine, ticlopidine), complications of intestinal infections.

## Clinical course

- severe, violent,
- Patient at risk of ischemia + CNS hemorrhage + renal failure,
- There may be extensive bleeding into the skin,
- Acute forms with relapses of thrombocytopenia / chronic forms.

## Therapy

- **Recurrent forms** – immunosuppressants (prednisone, cyclophosphamide), rituximab,
- **Idiopathic forms** – based on administration of fresh frozen plasma + plasmapheresis,
- **Secondary forms** – therapy of the underlying disease, discontinuation of suspected drugs,
- **Hemolytic uremic syndrome (HUS)** = organ limited form of TTP,
  - **Epidemic form** – childhood disease, preceded by enterocolitis (E. coli); hemolytic anemia, thrombocytopenia, renal impairment; th.: anti-infective + symptomatic th., or temporary hemodialysis,

- **Sporadická forma** – intestinal symptomatology is absent, symptoms are more varied; th.: plasmapheresis.

## Allergic thrombocytopenic purpura

- Similar to the acute form of ITP,
- Remedies (quinidine, sulfonamides ), food components → circulating immunocomplexes .

## Post-transfusion thrombocytopenia

- By the action of immunocomplexes, which are created by immunization with components of blood products (mainly plasma proteins, leukocyte antigens ) with an affinity for platelets,
- About a week after the blood transfusion,
- Even as a result of incompatibility in platelet antigens.

## Neonatal thrombocytopenia

- Similar to neonatal hemolytic anemia ,
- Action of antibodies against fetal platelet antigens.

## Heparin-induced thrombocytopenia (HIT)

- About 3% of patients,
- Type I – occurs within 2 days after administration, caused by direct reaction of heparin with platelets, leads to mild thrombocytopenia, which resolves within 4 days after discontinuation of heparin,
- Type II - occurs within 5-14 days of administration, caused by the formation of anti-platelet factor 4 antibodies that bind to and activate platelets in a complex with heparin, which can lead to thromboembolic complications in up to a third of patients with type II HIT.<sup>[3]</sup>

## Thrombocytopenia from increased losses

- Sometimes in the case of major bleeding, polytrauma, complicated surgical procedures, which are covered by transfers of stored blood,
- Also during operations using extracorporeal circulation .

## Thrombocytopenia from increased sequestration

- By increasing the retained pool of total platelet mass outside the circulation,
- Most often in splenomegaly.

## Links

### Related articles

- Thrombocytopenia of the newborn
- Hematological examination
- Pre-transfusion examination
- Examination of blood coagulation
- Purpura

### External links

- Trombocytopenie (Czech wikipedia)
- Thrombocytopenia (English wikipedia)
- Trombocytopenie.cz (<http://www.trombocytopenie.cz/clanek.php?id=2&tab=pacient>)

### Reference

1. KLENER, P. *Vnitřní lékařství*. 3. edition. Praha : Galén, 2006. ISBN 80-7262-430-X.
2. LEBL, J – JANDA, J – POHUNEK, P. *Klinická pediatrie*. 1. edition. Galén, 2012. 698 pp. pp. 552-554. ISBN 978-80-7262-772-1.
3. AHMED, I – MAJEED, A – POWELL, R. Heparin induced thrombocytopenia: diagnosis and management update. *Postgraduate Medical Journal* [online]. 2007, y. 83, vol. 9, p. 575-582, Available from <<https://pmj.bmj.com/content/83/983/575.full>>. ISSN 1469-0756.

### References

- KLENER, P, et al. *Vnitřní lékařství*. 3. edition. Praha : Galén, 2006. ISBN 80-7262-430-X.

### Video

