


Rapidly progressive glomerulonephritis

We thus refer to glomerulonephritis, which rapidly progress to renal insufficiency, over the course of weeks or days. They are extremely rare in children, most patients belong to adolescents.

Rapidly Progressive Glomerulonephritis:

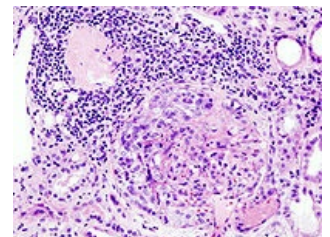


Etiopathogenesis

Etiologically, RPGN can be primary, i.e. without the presence of another renal or systemic disease, or secondary, i.e. in the course of other primary glomerulopathies or systemic disease.

According to the mechanism of formation, we distinguish 3 types of RPGN

- Type I = **antirenal**, with the presence of **antibodies against GBM**;
 - antibodies quickly destroy the capillary wall of the glomerulus;
 - genetic factors also play a significant role in pathogenesis, and etiological agents cause RPGN only in predisposed individuals.
- Type II = **immunocomplex**, with a high concentration of immunocomplex;
 - immunocomplex etiopathogenesis is the most common.
- Type III = **pauciimmune**, activation of immune mechanisms cannot be clearly demonstrated;
 - it is actually a picture of renal vasculitides, when no immune deposits are found in the kidneys.



Histology in ANCA-positive glomerulonephritis.

According to the presence of autoantibodies and immunofluorescent findings in the biopsy material

- Type I = ANCA-associated renal vasculitis
 - the finding of antibodies against the cytoplasm of neutrophil leukocytes when the immunofluorescence test is negative or only weakly positive (pauciimmune GN)
- Type II = GN with a positive finding of anti-GBM antibodies - anti-GBM nephritis
 - Goodpasture syndrome - linear immunofluorescence due to binding of antibodies to GBM
- Type III = Immune complex RPGN
 - IgA IgA nephropathy - with typically granular immunofluorescence

Pathological anatomy

All 3 mechanisms lead to a single morphological form - extracapillary proliferative GN, although they differ from each other in the immunofluorescence picture. Bowman's space is filled with proliferating epithelial cells (podocytes and Bowman's capsule cells). Fibrin is always detected in the area of proliferation, which proves the local activation hemocoagulation mechanisms.

Clinical picture

- Characterized by its difficult course from the beginning;
- Characterized by its difficult course from the beginning;
- the disease itself begins suddenly as an **acute nephritic syndrome with macroscopic hematuria, oligoanuria, and hypertension**;
- systemic symptoms (arthralgia, Raynaud's phenomenon, purpura) are rarer in children.

Laboratory

- **Changes in CBC** – anemia with schistocytes, manifestations of hemolysis, thrombocytopenia;
- **changes in serum protein electrophoresis** – hypergammaglobulinemia, increase in alpha-2-globulins and beta-globulins;
- **the picture of renal insufficiency** – decrease in GF, increase in urea, creatinine, phosphorus and potassium, hyponatremia, oliguria;
- **urinary findings** – erythrocyturia, erythrocytic cylinders, proteinuria (possibly nephrotic in nature);
- **metabolic acidosis**.
- Specific findings:
 - **type I** is characterized by positivity of anti-GBM antibodies;
 - For **type II**, a high level of circulating immune complexes, a decrease in C3 and C4 components of the complement system, increased concentration of cryoglobulins;
 - in **type III** we can demonstrate antibodies against the cytoplasm of neutrophil leukocytes ANCA.
- **c-ANCA** are antibodies directed against proteinase-3 in the cytoplasm of neutrophils (we find them in Wegener granulomatosis);
- **p-ANCA** are antibodies against myeloperoxidase (found in microscopic polyangiitis).

Diagnosis

It is based on the finding of acute nephritic syndrome and renal insufficiency. It is essential to perform a renal biopsy with findings of extracapillary glomerulonephritis and the corresponding immunofluorescence findings. Linear immunofluorescence of GBM in IgG is typical.

Therapy

- methylprednisone pulses 10–30 mg/kg, max. 1 g/d iv in short infusions, followed by prednisone therapy 1–2 mg/kg;
- immunosuppressants: cyclophosphamide 2–3 mg/kg/d, chlorambucil 0.15 mg/kg/d or cyclosporine A 5–5,5 mg/kg/d;
- plasmapheresis;
 - is today the *therapy of choice*;
 - removes anti-GBM antibodies, high concentrations of immune complexes, complement, coagulation factors and thrombocytes;
- anticoagulants: heparin;
- antiaggregation drugs: dipyridamole, ticlopidine;
- kidney Tx transplant
 - after kidney Tx, type I recurs in the graft with a frequency of 10–30% - Tx is recommended only after several months of immunosuppressive and hemodialysis with the disappearance of anti-GBM antibodies.

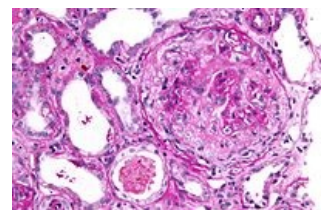
Prognosis

The prognosis of RPGN is very serious.

Goodpasture syndrome

 For more information see Goodpasture Syndrome.

Antibodies bind not only to the basement membrane of glomerular capillaries, but also to the basement membranes of pulmonary capillaries. It is assumed that overall toxic factors (especially nicotine) are involved in the development of the genetically determined terrain. Laboratory findings and diagnosis are identical to type I RPGN, i.e. **antirenal** type, with the presence of **antibodies against GBM**. Circulating IgG anti-GBM antibodies can be demonstrated and the titer is an indicator of the severity of nephritis.



Histology in anti-GBM glomerulonephritis.

Clinical picture

Hematuria, hemoptysis, cough, stuffiness and rapid development of renal insufficiency are characteristic. It very quickly leads to terminal kidney failure. Pulmonary symptoms usually precede renal damage. Pulmonary hemorrhage, hemoptysis, and dyspnea. Bleeding into the alveoli will appear on the X-ray image of the lungs in the form of diffuse cloudy shadows, located bilaterally and converging in the hilums. The patient has a restrictive ventilation disorder. Siderophages in the sputum and the disease often results in the picture of idiopathic pulmonary hemosiderosis. Renal lesions are characterized by microscopic hematuria, small proteinuria with rapid progression to renal failure. Oliguria.

Therapy

Plasmapheresis has the greatest application to remove IgG anti-GBM antibodies and stop damage to target organs. The treatment protocol includes treatment with corticosteroids, cyclophosphamide for at least 3 months.

Links

Related articles

- Acute glomerulonephritis
- Acute renal failure

Source

- HAVRÁNEK, Jiří: *Rychle progredující glomerulonefritida*.