

Quadrangular Space

English: *Quadrangular space*

Latin: *Foramen humerotricipitale*



Borders

The quadrangular space is an intermuscular space through which the axillary nerve and posterior circumflex humeral vessels pass through backwards to encircle the surgical neck of the humerus. It is bounded above by subscapularis and teres minor and below by teres major. The long head of triceps and the surgical neck of the humerus are medial and lateral boundaries, respectively.

Content

- posterior humeral circumflex artery from axillary artery)
- posterior humeral circumflex vein
- axillary nerve.

Links

Related articles

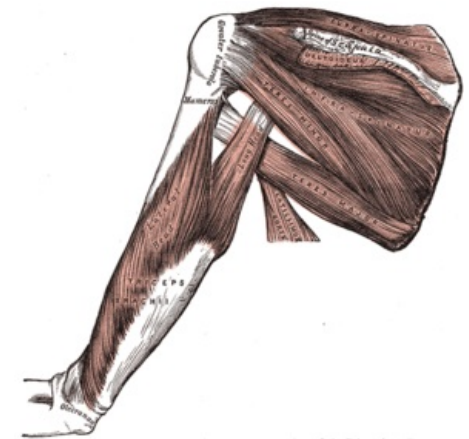
- Triangular Space

External links

- Photo at tufts.edu (<http://iris3.med.tufts.edu/dentgross/labguide/Shoulder4.html>)

Bibliography

- PETROVICKY, Pavel, et al. *Anatomie s topografií a klinickými aplikacemi : Sv. 1, Pohybové ústrojí*. 1. edition. Martin : Osveta, 2001. 463 pp. ISBN 80-8063-046-1.



Foramen humerotricipitale