

Popliteal Fossa

English: *Popliteal fossa*

Latin: *Fossa poplitea*



Boundaries

- *superior and medial:* the semitendinosus muscle and semimembranosus muscle;
- *superior and lateral:* the biceps femoris muscle;
- *inferior and medial:* the medial head of the gastrocnemius muscle;
- *inferior and lateral:* the lateral head of the gastrocnemius muscle .

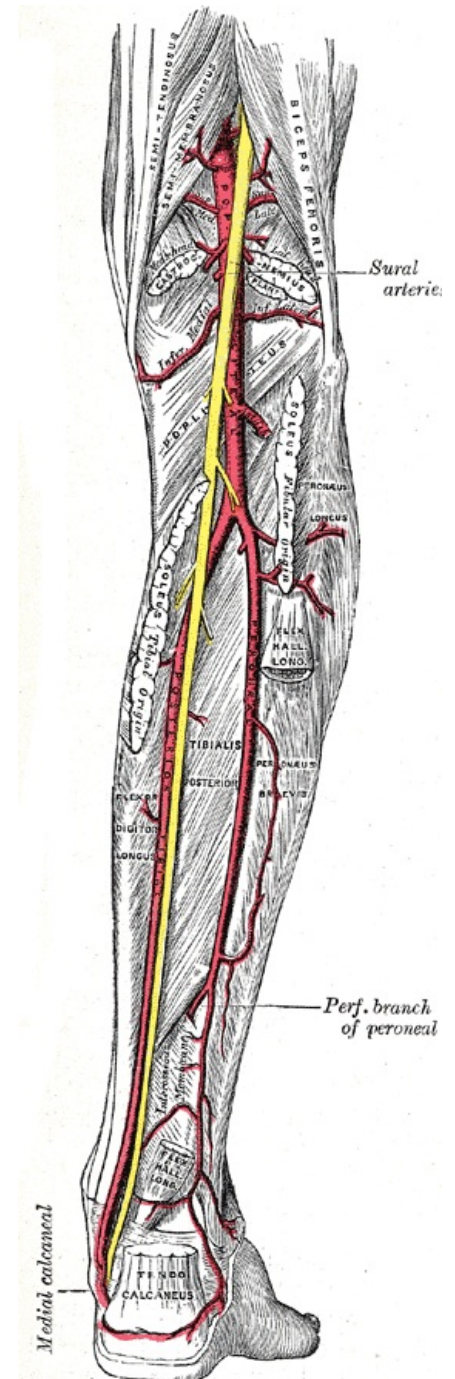
Contents

- popliteal artery and vein;
- tibial nerve;
- common peroneal nerve;
- popliteal lymph nodes.

Links

Bibliography

- PETROVICKY, Pavel, et al. *Anatomie s topografií a klinickými aplikacemi : Sv. 1, Pohybové ústrojí. 1.* edition. Martin : Osveta, 2001. 463 pp. ISBN 80-8063-046-1.



Popliteal fossa