

Poliomyelitis anterior acuta

Template:Infobox - disease

Poliomyelitis anterior acuta, also known as polio (transmissible) or Heine-Medin disease, is an epidemic summer virus. It is caused by the non-enveloped ssRNA Poliovirus from the genus Picornaviridae. *Poliovirus* has 3 antigenic types without crossimmunity.



Given that anterior acute poliomyelitis has already been eradicated in the Czech Republic, it is possible to encounter so-called polio-like syndromes or poliomyelitis acquired abroad. "Polio-like syndromes" are manifested by peripheral paresis and muscle atrophy in the area of one or two joints. Sensory disturbances are not usually present, but pain may occur. EMG shows signs of an acute motoneuron lesion.^[1]

Features

The course of the disease is often silent and is limited to the gastrointestinal tract - water and food can be contaminated this way. It is transmitted through the patient's stool. It selectively affects the **frontal horns of the spinal cord'** and the *motor nuclei of the trunk*. It has the same clinical picture as *echoviruses* and *Coxsackie* viruses.

Epidemiology

In Czechoslovakia, the incidence has been zero since 1957 (we are the first country in the world to do so). *Poliovirus* has **3 antigenic types - I, II, III'** and man is the only natural host of virusu. Viremia and penetration into the CNS will only occur in a small percentage.

Eradication^[2]

We divide the regions into:

- **endemic:** Afghanistan, Nigeria, Pakistan,
- and **non-endemic:** Central African Republic, Chad, Ivory Coast, Democratic Republic of Congo, Ethiopia, Israel, West Bank, Gaza Strip, Kenya, Liberia, Mali, Niger, Somalia, Uganda. ^[3]

The European region was declared polio-free in June 2005. The risk of importation of poliomyelitis is still looming.

WHO Polio Eradication Program^[2]

- Virological examination of patients with weak paresis.
- Investigation of contacts.
- Compulsory reporting.
- Expert analysis of isolates.

Pathology

Infiltration of lymphocytes and granulocytes around stem motor nuclei and anterior horn cells spinal.
Proliferation of microglia.

Clinical symptoms

Incubation period: **5-14 days'** ^[4]. **flu symptoms** appear - fatigue, temperature, sweating, headache, digestive problems. What follows is **healing'**.

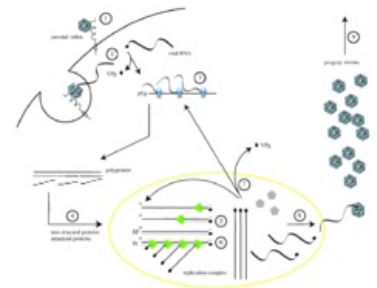
Only a fraction progresses to meningitis → headache, back pain, limb pain, meningeal symptoms, muscle stiffness = **preanalytical stage'' (or meningeal)**. **In about 2% it progresses in the nervous system = paralytic stage.**

The course is most often ``asymptomatic. *All stages leave an **immunity'** to the virus. The spread of the virus is aided by its excretion in the stool (3 months after the infection subsides).*

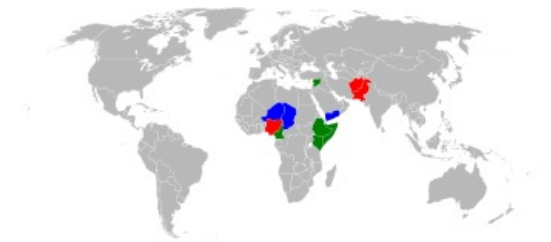
Spinal form

Affects the *front* (sometimes lateral) horns of the spinal cord. There are muscle fasciculations and pain. Paresis and vegetative manifestations develop within 24 hours. It can also affect the respiratory muscles.

Stem form



Poliovirus life cycle



Worldwide spread (year 2013)

It leads to paresis of the pharynx, larynx, tongue, and facial expressions with possible spread to the respiratory muscles and the heart. Improvement occurs as early as a week after the development of nerve symptoms and continues up to 1 year. It leaves **serious lasting effects**'. Residual peripheral paresis affecting various muscle groups of the limbs and trunk, muscle contractures.

Diagnosis

- Clinical picture + examination of CSF (cytoprotein association).
- Virus isolation from stool, rise of specific antibodies in cerebrospinal fluid and serum (confirmation of diagnosis).

Differential diagnosis

Other acute meningitis, polyradiculoneuritis, transverse myelitis.

Treatment and Prevention

In the acute phase of the disease, physical *rest* and *drinking regimen* are the most important. In severe forms (ascending Landry's palsy), intensive care is needed (UPV - mainly negative pressure ventilation, using the so-called iron lung). It is a continuous long-term process. Interdisciplinary medical cooperation and parental cooperation are important.

Prevention

Mortality reached up to 25% in the epidemic, the last one in our country in 1960. A fundamental change was brought about by the introduction of active immunization in 1957, when vaccination with **inactivated (Salk) vaccine began. Since 1960, vaccination with the `oral live vaccine (Sabin) has been started.**

Since 2007, based on WHO recommendations, the Czech Republic has again been vaccinated with an "inactivated" vaccine, which is administered as part of a "hexavaccine" or as a "monovaccine" in five doses. The reason for switching to an inactivated vaccine is the fact that when using it, the virus is not excreted in the stool or the virus mutates, so there is no risk of post-vaccination poliomyelitis.^[5]

Prognosis

Good for all forms except paralytic. Lethality of the paralytic form is **5-15%**, survivors no longer recover. Unusual fatigue, joint and muscle pain, further weakening of the muscles, probably due to overloading of functioning muscle groups.

Preference is given to placing the child in a normal group. Another option is the Jedlička Institute in Prague.

Post-polio syndrome

Usually during the **20 years of peace** after stabilization of the clinical residue after the *paralytic form* of poliomyelitis. The cause is **overload and dysfunction** of the remaining motoneurons of the anterior horns of the spinal cord.

Symptoms: increased fatigue, muscle weakness (even in previously unaffected segments), fasciculation, pain in affected muscles and joints.

Therapy: non-specific, includes supportive orthoses and gentle rehabilitation.



A man who had polio

Links

Related Articles

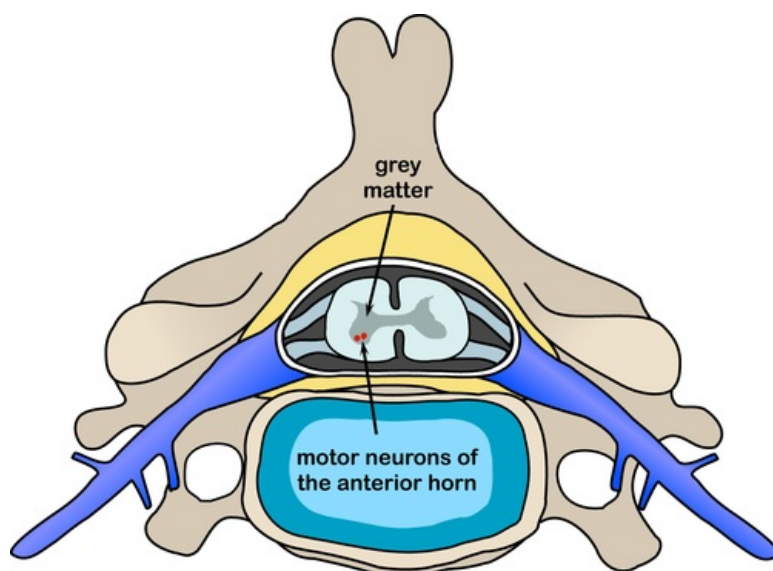
- Viral infections of the nervous system
- The most common syndromes and diseases of pediatric neurology/PGS
- Cerebral Palsy
- Poslední cesta viru dětské obrny (<https://jsme.cz/posledni-cesta-viru-detske-obrny>)

External links

- Dětská obrna
- Dětská obrna (anglická Wikipedie)

Reference

1. EHLER, E – DERŽÁKOVÁ, M – LATTA, J. , et al. Akutní polyradikuloneuritida – diferenciální diagnostika. *Neurologia pre prax* [online]. 2011, y. 12, p. 180-181, Available from <http://www.solen.sk/index.php?page=pdf_view&pdf_id=5109>.
2. ŽAMPACHOVÁ, Eva. *Přednášky a materiály dr. Žampachové ke stažení* [online]. [cit. 2012-01-27]. <<http://mujweb.cz/?redirected=1521314685>>.
3. WHO. *The Global Polio Eradication Initiative - Infected countries* [online]. [cit. 2013-10-



Motoneurons of the anterior horns of the spinal cord

- 26]. <<http://polioeradication.org/Infectedcountries/Importationcountries/Israel,WestBankandGaza.aspx>>.
4. SEIDL, Zdeněk – OBENBERGER, Jiří. *Neurologie pro studium i praxi*. 1. edition. Grada Publishing, 2004. ISBN 80-247-0623-7.
 5. STAŇKOVÁ, Marie – VANIŠTA, Jiří. *Medicabáze.cz - Poliomyelitida* [online]. ©2008. [cit. 6. 2. 2010]. <http://medicabaze.cz/?&sec=term_detail&termId=1619&tname=Poliomyelitida>.

Bibliography

- SOSNA, A. – VAVŘÍK, P. – KRBEC, M., et al. *Základy ortopedie*. 1. edition. Praha : Triton, 2001. pp. 152. ISBN 80-7254-202-8.
- DUNGL, P., et al. *Ortopedie*. 1. edition. Praha : Grada Publishing, 2005. ISBN 80-247-0550-8.
- SEIDL, Zdeněk – OBENBERGER, Jiří. *Neurologie pro studium i praxi*. 1. edition. Praha : Grada Publishing, 2004. ISBN 80-247-0623-7.
- NEVŠÍMALOVÁ, Soňa – RŮŽIČKA, Evžen – TICHÝ, Jiří, et al. *Neurologie*. 1. edition. Praha : Galén, 2002, 2005. 368 pp. ISBN 80-7262-160-2,.