

# Pleural puncture and drainage (pediatrics)

## Pleural puncture (pediatrics)

### Urgent indication

- *pneumothorax*, especially tension.

### Execution

- child is in a supine position;
- if there is time, we will perform adequate analgosedation;
- the injection is made above the upper edge of the rib in the medioclavicular line in the 2nd-3rd. intercostals.

**⚠ The upper edge of the rib must be respected because of possible injury to the nerve-vascular bundle that runs along the lower edge of the rib**

- 2nd intercostal is located immediately below the clavicle;
- we preferably use i.v. "blue" cannula (22G cannula for newborns, 18G cannula for the elderly);
- after penetration into the interpleural space, we pull out the needle and introduce the cannula deeper;
- urgent air evacuation is carried out using a syringe, otherwise it is better to connect the cannula using a connecting tube and a three-way cock to a 20 ml syringe, which we then evacuate the air;
- in the case of a super-urgency with a tension PNO, we convert the tension PNO to an open one using a needle or, better, a set of needles.

Definitive treatment consists in the introduction of a chest drain with active suction;

- the patient is in a supine position, the affected side can be slightly supported, the hand on the affected side is raised behind the head;
- the injection site is the 4th or 5th intercostal space between the front and middle axillary lines, we disinfect the injection site, cover and infiltrate with 1% mesocaine;
- at the injection site, we make a small horizontal skin incision with a scalpel, through it we then bluntly penetrate the upper edge of the rib (again, we must protect the nerve-vascular bundle running along the lower edge); drain is captured in the pean and introduced into the pleural cavity;
- penetration is manifested by a sudden loss of resistance;
- we close the incision, fix the drain and connect it to continuous suction with negative pressure (*system according to Bülau or aqua seal*).

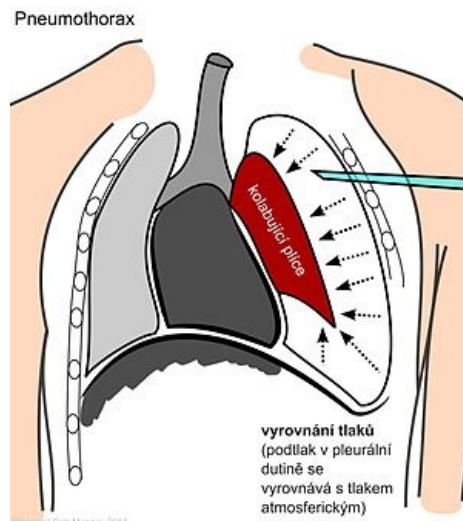
## Drainage of the pleural cavity (pediatrics)

### Indication


- evacuation of pleural fluid that causes respiratory distress;
- collection of pleural fluid for diagnostic purposes.

### Execution

- pleural puncture is performed in children sitting in the 7th or 8th intercostal space in the posterior axillary line (roughly at the level of the tip of the scapula with the arm raised), or in the 5th or 6th intercostal space in the middle axillary line (on the right we inject one intercostal space above);
- adequate analgosedation / local anesthesia is a matter of course, preferably  $S_aO_2$  monitoring during the procedure;
- we conduct the puncture continuously, perpendicular to the chest wall at the upper edge of the rib into the pleural cavity;
- after piercing the parietal pleura, the direction of the needle is bent tangentially towards the spine, bringing the tip of the needle closer to the parietal pleura;
- we put a three-way cock on the needle/catheter so that air cannot penetrate into the pleural cavity and at the same time it is possible to aspirate pleural fluid;
- after the end of the puncture, we quickly remove the needle and cover the puncture site with a compression



Scheme of puncture of an extensive left-sided pneumothorax



Drainage systems in pediatric patients

bandage and perform a control lung X-ray.

## Complications

- pneumothorax;
- hemothorax;
- infections;
- liver injury, spleen, lung, diaphragm, heart.

## Differential diagnosis of pleural exudate and transudate

### *Transudate*

- pH > 7.2;
- protein P/S (pleural fluid/serum) < 0.5;
- LDH P/S < 0.6;
- glucose (mmol/L) < 2.22;
- leukocytes < 1000.

### *Exudate*

- pH < 7.2;
- proteins P/S > 0.5;
- LDH P/S > 0.6;
- glucose (mmol/l) > 2.22;
- leukocytes > 10,000.

## Links

## Source

- HAVRÁNEK, Jiří: *Pleural puncture and drainage*. (edited)

## Related Articles

- Pleural effusion
- Hemothorax
- Chylothorax
- Empyema
- Fibrothorax
- Light's Criteria
- Neonatal pneumopathy