

# Pigment

**Pigment** - colored substance inorganic and organic, intra- and extracellular, soluble or corpuscular.

The main one pigment surface human of the organism is **melanin** contained in *skin*, *hair* and *eye*. Inside the body it is heme and the bilirubin it produces, both related to the most abundant pigment in nature - chlorophyll - leafy green.

Endogenous (arise directly in the organism)	<ul style="list-style-type: none"> <li>▪ <b>autogenous</b> (arise at cellular metabolism)</li> </ul>	<ul style="list-style-type: none"> <li>▪ <b>melanin</b> (oculocutaneous, neuromelanin)</li> <li>▪ <b>lipopigments</b> (ceroid, lipofuscin, lipochrome)</li> </ul>
	<ul style="list-style-type: none"> <li>▪ <b>hematogenous</b> (arise by transformation hemoglobin)</li> </ul>	<ul style="list-style-type: none"> <li>▪ <b>hemosiderin</b> (<math>\text{Fe}_2\text{O}_3 \times n\text{H}_2\text{O}</math> complex with proteins)</li> <li>▪ <b>hematoidin</b> (bilirubin crystals extracellularly)</li> <li>▪ <b>hemofuscin</b> (mixture of ceroid with hemosiderin)</li> <li>▪ <b>hematin</b></li> <li>▪ <b>bilirubin</b> (formed by the decay of heme)</li> <li>▪ <b>porphyrins</b></li> </ul>
Exogenous (are supplied to the body from the outside)	<ul style="list-style-type: none"> <li>▪ <b>by injury</b> (tattoo, siderosis)</li> </ul>	
	<ul style="list-style-type: none"> <li>▪ <b>GIT and via blood</b> (argyrosis, chrysocyanosis, PbS)</li> </ul>	
	<ul style="list-style-type: none"> <li>▪ <b>by inhalation</b></li> </ul>	<ul style="list-style-type: none"> <li>▪ <b>simple pigmentation</b> (anthracosis, tobacco, stannosis)</li> <li>▪ <b>pneumoconioses</b> (silicosis, asbestosis, berylliosis, talcosis)</li> </ul>

## Endogenous pigments

### Autogenous pigments

#### Melanin

Melanin is a polymer of metabolites tyrosine or dopamine (protein-bound polyindolquinone). It is usually **yellow-brown** to **black** in colour. It is stored intracellularly in melanosomes (derived from Golgi complex) or in lysosomes, is decolorized by oxidizing agents reagents ( $\text{H}_2\text{O}_2$ ), is argentaffinic (reduces ammoniacal silver solution - Masson reaction).

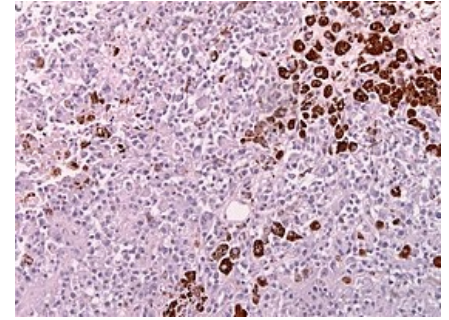
 For more information see *Melanin*.

#### Disorders in melanin pigmentation

1. **Hyperpigmentation** (diffuse - Addison, focal - chloasma, melanoderma, melanoma):
  - **Addison's disease** (peripheral type) – panhypocorticalism (insufficiency of the adrenal cortex) from adrenal causes, as a result of the decrease in blood cortisol concentration, the production of ACTH and MSH is increased (they have a common precursor POMC - proopiomelanocortin), resulting in generalized hyperpigmentation of the skin, especially accentuated in areas with physiologically increased pigmentation (linea alba, perianal and perigenital area), exposed to sunlight (hands, face) and at the site of skin scars, as well as focal melanin pigmentation of the buccal mucosa at site 1. In the buccal area, buccal pigmentation is present in the upper molars (graphite spots);
  - **hyperfunction of the pituitary gland;**
  - Peutz-Jeghers syndrome;
  - **transient diffuse hyperpigmentation** after exposure to radiation (sun exposure), people with sensitive skin develop freckles (*ephelides*) that may be permanent;
  - **chloasma** - a yellow-brown spot caused mainly by hormonal influences, in pregnancy (*chloasma uterinum*) or when taking hormonal contraceptives;
  - **melanoderma** - hyperpigmentation of the skin due to various causes, e.g. radiation, chemicals, trauma, inflammation;
  - **melanosis of smokers** - hyperpigmentation in the oral cavity and on the hands of heavy smokers;
  - **neurofibromatosis** - spots of the colour of white coffee on the skin;

- **melanoma** - a tumour made of melanocytes (tumour cells are called melanoblasts);
- **hemochromatosis** - general hyperpigmentation of the skin;
- 2. **Depigmentation** (congenital - albinism, acquired - vitiligo, leukoderma);
  - **vitiligo** - postnatally occurring mottled depigmentation of the skin, spots are sharply demarcated, hair is white, probably due to autoimmune blockade of melanocyte function (melanosomes are not altered but contain little pigment);
  - **leukoderma** - localized loss of pigment (pale spots without sharp borders) after persistent skin inflammation, due to destruction of melanocytes;
  - **albinism** - an inherited (AR) metabolic disorder leading to partial or complete absence of melanin.

Also important for pigment pathology is **alkaptonuria** (a defect in homogentisate-1,2-dioxygenase, which catalyzes the conversion of homogentisate to maleinyl acetate, resulting in the accumulation of acid. homogentisate - excretion into urine, dark urine), **ochronosis** (oxidation and polymerisation of homogentisate and binding to connective tissue proteins - joint, especially spinal, involvement).

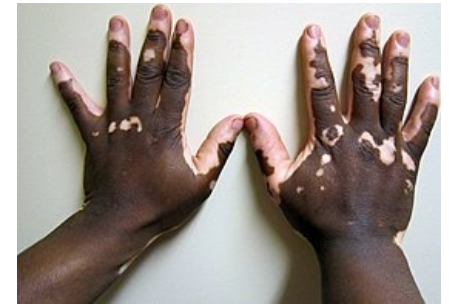

Melanoma

## Lipopigments

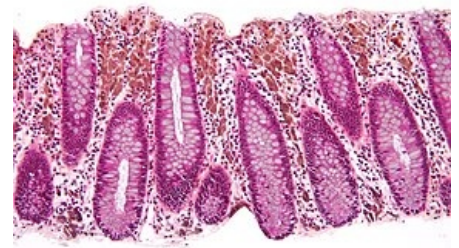Lipopigments are **yellow-brown** to **brown** pigments that are formed in autophagic **lysosomes** by the polymerization of unsaturated fatty acid peroxidation products.

1. **Ceroid + lipofuscin** - brown pigments insoluble in fats, stained with Sudan, PAS+, fluoresce in UV, are argentaffin (ceroid is considered to be a precursor of lipofuscin - it is more sudanophilic and less reducing of silver solution than lipofuscin) - the formation of these pigments is generally influenced by the ratio of pro - (mainly heavy metals like Fe) and antioxidant (mainly vitamin E) factors, peroxidation mainly affects pathologically accumulated lipids (steatosis, lipidosis) or directly cell membranes.
  2. **Lipochrome** (lutein) - exogenous pigment formed from carotenoids (obtained alimentarily), soluble in fats, but its presence in the body is constant, it occurs dissolved (non-corpusecular pigment) in adipose tissue, whose yellow-orange colouring it determines.
- **Ceroid** (occurrence) - macrophages around haematomas (mixture of ceroid with haemosiderin is referred to as **haemofuscin**), lysosomal accumulation of lipids (e.g. in macrophages in steatosis and lipidosis), in muscle (small intestine, myocardium, etc.) in avitaminosis E, in colonic mucosa (permeated with pigmentophages, unclear pathogenesis) - *melanosis coli* (as opposed to pseudomelanosis, which is a greenish discoloration of the abdominal wall and abdominal organs due to postmortem diffusion of gases -  $H_2S$  from the intestines acts on hemoglobin in the blood vessels and turns it into verdohemoglobin).



Vitiligo

*Melanosis coli* - benign pigmentation, occurs with chronic use of laxatives (deposition of anthraquinone pigments released from the drug).



Melanosis coli



- **Lipofuscin** - so-called wear pigment (increases in old age, especially in cells with low mitotic activity - so-called brown atrophy - *atrophia fusca*), occurs in the following organs: liver (hepatocytes mainly in the centre of the liver lobules), myocardium (forming caps over the nuclei of cardiomyocytes), adrenal glands (*zona reticularis*), nerve cells, skeletal muscles.
- **Lipochrome** - normally occurs in adipose tissue, pathologically multiplied in increased dietary intake of carotenoids (e.g. in diabetes), when the yellow fat of the subcutaneous tissue, palm and plantar areas (xanthosis) and skull base is increased, differential diagnosis is necessary to distinguish carotinemia from icterus - in **carotinemia there is no yellowish** coloration of **sclerae**.

## Hematogenous pigments

These pigments arise from degradation of hemoglobin. Disorders of haematogenous pigmentation include both disorders of **intrinsic haematogenous pigments** (haemosiderosis) and disorders of **biosynthesis** (porphyria) or **degradation** (icterus) of haem. Hemoglobin is released during the breakdown of erythrocytes, hemolysis. That can be intravascular or extravascular. Hemoglobin is broken down into globin, biliverdin and  $Fe^{3+}$ .

 For more information see Hemolysis .

- **Hemosiderin** - a complex compound containing ferric hydroxide with proteins, polysaccharides and lipids, forms rusty brown grains in HE (evidence to distinguish it from lipofuscin - Perls reaction - Fe in hemosiderin forms a blue colour with potassium ferrocyanide (Berlin blue) in acidic media), is almost always **intracellular**

within macrophages (siderophages).

- **Hematoidin** - chemically identical to bilirubin, forms red-yellow rhombic to needle-like crystals in older hematomas, is almost exclusively **extracellular**, does not contain Fe (Perls reaction negative).
- **Hemofuscin** - mixture of hemosiderin with ceroid in hematomas (intracellularly in histiocytes).
- **Hematin** - brown pigment similar to hemosiderin, but Fe is tightly bound (Perls), occurs at the base of acute gastric ulcer (where it is formed by the action of HCl on hemoglobin), causes the color of dry gangrene.

### Conditions with excess hematogenous pigments

- **Hemosiderosis** - excessive deposition of hemosiderin in the RES (mainly Kupffer cells of the liver in periportal areas, spleen, nodules - pigmentation of endothelial rafts), deposition leads to a small increase in connective tissue, hemosiderin enters the kidneys via the blood route and is deposited there in the proximal tubule cells. Hemosiderosis is not a disease entity, but only a symptom of **increased hemolysis**; it also accompanies repeated transfusions in anemias (changes more reminiscent of hemochromatosis - secondary hemochromatosis) or in alcoholics, where there is increased absorption of iron from the GIT due to alcohol - accumulation of iron pigment in hepatocytes (siderosis).

 For more information see Hemolytic anemia.

- **Hemochromatosis** - conditioned by increased iron absorption in the duodenum (dietary iron is in the form of  $\text{Fe}^{3+}$ , in the stomach is reduced to  $\text{Fe}^{2+}$  and in this form it is also resorbed, in enterocytes it is again oxidized to  $\text{Fe}^{3+}$  and is either stored as ferritin or transported by transferrin), excess iron is deposited in the RES cells similarly to **hemosiderin** (the spleen is less affected, in the kidney it is deposited in the cells of the distal tubules), is accompanied by a pronounced fibroproduction (in the liver it can lead to the so-called. It also affects other organs (pancreas + skin pigmentation - bronze diabetes, salivary glands, bile ducts, *plexus chorioideus*).

 For more information see Hemochromatosis.

- **Haemoglobinaemia** - accompanies severe haemolysis (e.g. during transfusions of incompatible blood), when haptoglobin is depleted and the RES cannot process all haemoglobin. Hemoglobin enters the renal tubules - hemoglobinuria, hemoglobinuric nephrosis.
- **Icterus** - jaundice, causes yellow skin, sclerae, mucous membranes.

 For more information see Icterus.

## Exogenous pigments

the method of exogenous pigmentation is threefold:

1. **Pigmentation by injury** - most often affecting the skin and eye, usually by wounding (sand impaction, gunshot wounds and penetration of iron splinters into the skin - siderosis, particles of copper or its alloys (brass) - chalcosis, decorative tattooing - pigmentation of joints).
2. **Pigmentation by the gastrointestinal tract and via blood** - produced by certain metals and their salts that are absorbed by the GIT mucosa and distributed by the blood to various tissues.
  - **Argyrosis** - grey pigmentation with silver, accumulates mainly in the basal membranes of the sweat glands or in the conjunctiva during long-term administration of eye drops with  $\text{AgNO}_3$ .
  - **Chrysocyanosis** - bluish discoloration after administration of colloidal gold *i.v.* (rheumatoid arthritis).
  - **Lead gingival lining** - formed by PbS (influence of bacterial sulphate) in chronic intoxication with Pb and other heavy metals (Bi, Sb...).
3. **Pigmentation by inhalation** - inhaled particles larger than  $10\text{ }\mu\text{m}$  are trapped in the nose and nasopharynx, between  $5$  and  $10\text{ }\mu\text{m}$  are trapped in bronchial and bronchiole mucus and are coughed up or diverted by ciliary transport, particles smaller than  $5\text{ }\mu\text{m}$  reach the alveoli, where they are taken up by alveolar macrophages (conioophages), which are either coughed up with the absorbed pigment or pass into the connective tissue interstitium of the alveoli, from which they may enter the lymph nodes via lymphatic vessels (an example of lymphogenic metastasis of pigment).
  - **Simple pigmentation** - pigment particles are inert (anthracnose, tabacose, stannose).
  - **Pneumoconiosis** - particles induce fibroproduction (silicosis, asbestosis, berylliosis, talcose, aluminosis).

### Anthracosis

Simple pigmentation with amorphous carbon (soot), it is inert to lung tissue (it does not cause fibroproduction), but it is deposited in increased amounts in fibrosis foci (e.g. tuberculous foci) - so-called slate induction (*induratio nigra*).

 For more information see Anthracosis.

### Tabacosis

Brown discoloration of the lungs by tobacco dust, does not cause special disorders.

### Stannosis

Dusting of the lungs with tin dioxide ( $\text{SnO}_2$ ), does not cause clinical disorders.

## Silicosis

Lung damage caused by inhalation of inorganic material - in this case fibrogenic silica particles  $\text{SiO}_2$ .

 For more information see *Silicosis*.

## Asbestosis

Dusting of the lungs with asbestos fibres (magnesium silicate).

 For more information see *Asbestosis*.

## Berylliosis

Formation of tuberculoid granulomas.

## Farmer's lung

Pneumonitis arising from a hypersensitivity background, caused by inhalation of dust from wet hay containing the microorganism **Micropolyspora faeni**.

# Links

## Related articles

- Phototypes
- Pigmentation disorders
- Melanoma
- Skin Anatomy
- Skin physiology

## External links

- Biological pigment (English wikipedia)
- Pigment (Czech wikipedia)

## Source

- PASTOR, Jan. *Langenbeck's medical web page* [online]. ©2005. [cit. 2011-03-08]. <<https://langenbeck.webs.com/>>.

## References

- STRŽÍTESKÝ, Jan. *Patologie*. 1. edition. Olomouc : Epava, 2001. ISBN 80-86297-06-3.
- PROMOTED, Ctibor – ŠTEINER, Ivo, et al. *General pathology*. 1. edition. Galen, 2011. 290 pp. ISBN 978-80-7262-773-8.