

# Periodontium

**The periodontium** is the supporting apparatus of the tooth. It is the tissue that surrounds and fixes the tooth in its position. It also serves as a barrier - it prevents the entry of bacteria, remains of food and other harmful noxes.

The periodontium is formed by the following structures:

- **gingiva** (gum),
- **cementum** (dental cement),
- **alveolar bone** (bone bed),
- **periodontium fibres**,
- **sulcus gingivalis** (gum groove).

Periodontology deals with diseases of the periodontium.

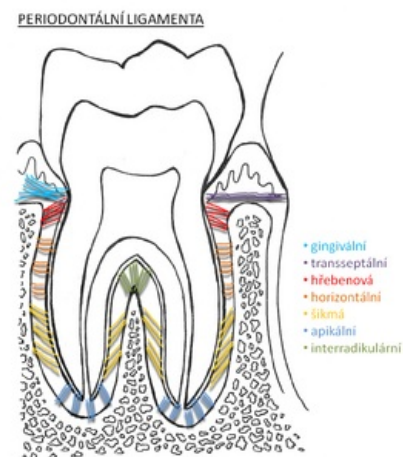
## Links

### Related articles

- Anatomy of the periodontium
- Damage to hard tissues and periodontium
- Periodontal disease
- Sharpey's fibres

### Sources

- HELWIG, Elmar – KLIMEK, Joachim, et al. *Záchovná stomatologie a parodontologie*. 1. edition. Praha : Grada Publishing, a.s, 1999. 0 pp. ISBN 80-247-0311-4.



Structure of tooth anchoring fibres