

Pectoralis Major

English: *Pectoralis major muscle*

Latin: *Musculus pectoralis major*



Pectoralis major muscle (lat. *musculus pectoralis major*) is a muscle on the anterior part of the chest.

Origin

It arises from the anterior surface of the sternal part of the clavicle (*pars claviculæ*), from the sternum (*pars sternalis*) and from the cartilages of the true ribs (*pars abdominalis*).

Insertion

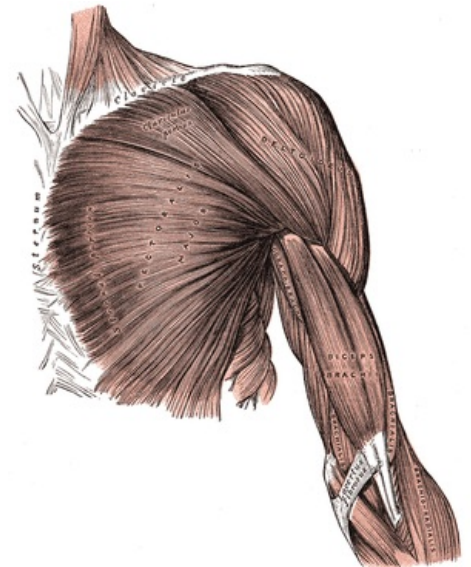
The muscle is inserted into the greater tubercle of the humerus.

Inervation

lateral (C8, Th1) and medial (C5–C7) pectoral nerves (plexus brachialis).

Function

- flexion of humerus;
- horizontal adduction;
- inward rotation;
- secondary inspiratory muscle.
- Pulling the humerus towards the midline of the body anteriorly.



Pectoralis major muscle

Links

Sources

Wikiskripta. *Musculus pectoralis major* [online]. Wikiskripta, ©2011. The last revision 2011-06-13, [cit. 2011-07-19]. <http://www.wikiskripta.eu/index.php/M._pectoralis_major>.