

# Non-epithelial ovarian tumors

**Non-epithelial ovarian tumors** can be either **germ cell tumors**, or **stromal and germ cell tumors** (*sex cord-gonadal stromal tumors*).

## Germinal tumors

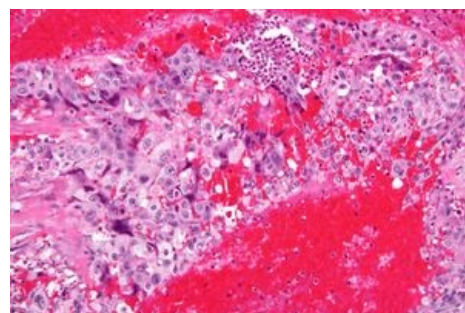
The tumors may be purely germinal and tumors mixed with germline tumors. Purely germinal can be<sup>[1]</sup>:

- **dysgerminoma** – is the most common malignant germ cell tumor and in 20% it affects both ovaries, it is chemo and radiosensitive (it is treated with chemotherapy); every (phenotypic) woman with karyotype 46, XY or the presence of SRY – is at high risk of developing malignant dysgerminoma - this is an indication to remove gonads<sup>[2]</sup>;
- **yolk sac tumor**;
- **embryonic carcinoma**;
- **polyembryoma**;
- **choriokarcinoma**;
- **teratoma**.

## Sex cord-gonadal stromal tumors

They can be from germline tissue, or from stromal tissue, or both (mixed), and can produce either estrogens, androgens, or both (gynandroblastoma). They are distinguished as follows:

- **granulosa tumors**;
- **thekoma/fibroma**;
- **androblastomas** (Sertoli tumor, Leydig tumor, Sertoli-Leydig tumor);
- **gynandroblastomas** (mixed male and female, can be mixed stromal and sex-cord, or one of these tissues).



Highly malignant choriocarcinoma

## Links

### Related articles

- Ovarian tumors
- Ovarian cancer
- Malignant tumors in gynecology

### External links

- [www.onkogyn.cz](http://www.onkogyn.cz) (<http://www.onkogyn.cz>)
- Sex cord-gonadal stromal tumour (wikipedia page)

### References

1. ROB, Lukáš – MARTAN, Alois – CITTERBART, Karel. *Gynekologie*. 2. edition. Praha : Galén, 2008. 390 pp. pp. 206–211. ISBN 978-80-7262-501-7.
2. ROB, Lukáš – MARTAN, Alois. *Gynekologie*. 2. edition. Praha : Galén, 2008. 390 pp. pp. 70,71. ISBN 978-80-7262-501-7.