



Nephritic syndrome

Nephritic syndrome (ICD-10) is defined as a set of the following symptoms:

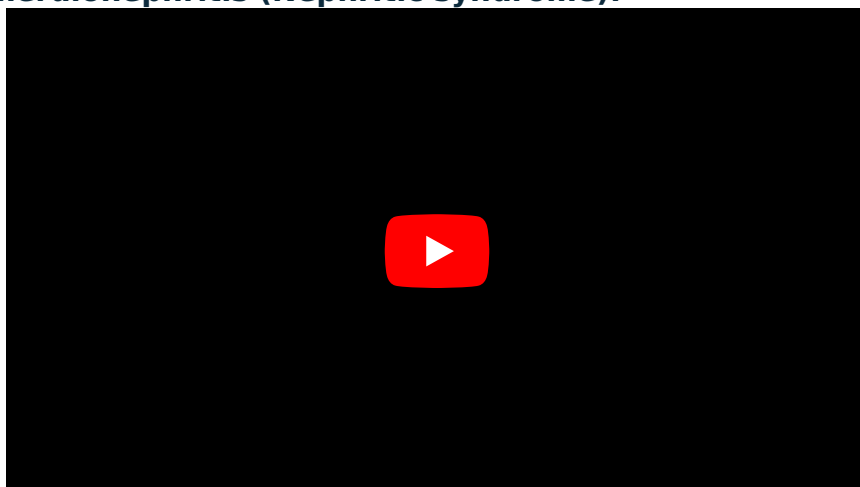Nephritis syndrome (glomerulonephritis):



Nephritis vs nephrotic syndromes causes:



Proliferative glomerulonephritis (Nephritic syndrome):



Chronic Kidney Disease (CKD) definition:

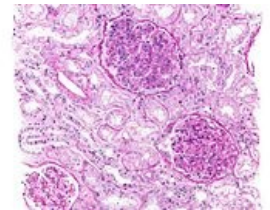


1. Hematuria (dysmorphic erythrocytes in urine).
2. Oliguria and azotemia.
3. Hypertension,
4. mild proteinuria and edema may occur, but not as much as in nephrotic syndrome.

Lesions caused by the nephritic syndrome have the following common features: *cell proliferation* within the glomerulus accompanied by a *leukocyte infiltrate*. The reaction resulting from inflammation destroys the capillary walls, erythrocytes leak into the urine, hemodynamic changes occur and subsequently a **decrease in GFR** (glomerular filtration). This manifests clinically as oliguria, fluid retention and azotemia. Acute nephritic syndrome can occur secondarily (SLE) or as a result of primary glomerular disease (e.g., postinfectious glomerulonephritis).

Acute postinfectious glomerulonephritis

- **Synonym:** Poststreptococcal glomerulonephritis,
- one of the most frequent glomerular disorders caused by deposits of immunocomplexes (IK), common in children and young adults,
- initial antigen can be:
 - endogenous (e.g. in SLE),
 - exogenous – β -hemolytic group A streptococci, pneumococci, staphylococci, viruses (mumps – mumps, measles, chicken pox, Hepatitis B, C),
- classically develops 1 to 4 weeks after recovery from group A strep infection,
- only certain (**nephritogenic**) strains of β -hemolytic streptococci are capable of causing the disorder.



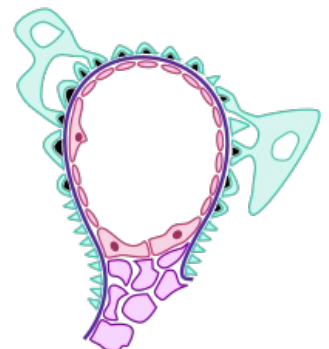
Histology of postinfectious GN

Pathogenesis

There is a **deposit of IK** (circulating and "in situ" complexes - eg C3 component of complement, binding of IgG to bacterial antigens captured on the glomerulo-basal membrane, GBM). Subsequently, typical signs of diseases from immune complexes such as hypocomplementemia develop.

Morphology

We observe a uniform **increased cellularity** of the glomerular bundle (throughout the glomerulus, we speak of diffuse GN) due to increased proliferation and edema of mesangial and endothelial cells. In addition, neutrophils and monocytes migrate there. A typical image in the electron microscope is the so-called **subepithelial humps** (in English **humps**) nestled against the GBM. With immunofluorescence, we see **granular deposits**, especially subepithelially.



Subepithelial humps schematically shown in black

Clinical course

The onset is sudden, the patient suffers from nausea, nausea, elevated temperature. Urine has a brownish tinge (strong hematuria), there is slight proteinuria. Examination of the serum shows a low level of complement, while the level of serum anti-streptolysins O antibodies is, on the contrary, elevated. In children, there are relatively frequent remissions, some may even develop **Rapidly progressive GN** (due to severe damage to the glomeruli with the formation of crescents ("sickles")).

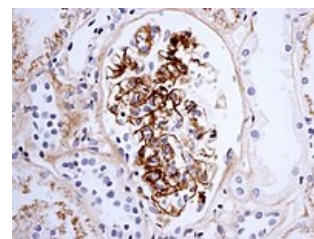
IgA nephropathy

 For more information see *IgA Nephropathy*.

- **Synonym:** Berger's disease,
- common in children and young adults,
- it is the most common glomerular disease detected by renal biopsies (worldwide).

Pathogenesis

Increased synthesis of IgA in the bone marrow (response to respiratory or GIT infection) and elevated serum level is observed in 50% of patients. Incorrect glycosylation can also occur. IgA immunocomplexes are subsequently deposited in the mesangium and activate complement alternative pathway.



IgA imaging in a patient with Henoch-Schönlein purpura

Morphology

The lesions vary greatly (segmental inflammation, diffuse mesangial proliferation). IF will show IK IgA in the mesangium, often with a small admixture of C3, IgG, or IgM. Components required for classical complement activation ($C1_q$ and C4) are missing.

Clinical course

The disease begins as gross (microscopic in 30–40% of patients) hematuria during nonspecific HCD infection. It lasts for a few days, then subsides to return every few months. Some experts consider IgA nephropathy to be a localized variant of Henoch-Schönlein purpura. Patients with celiac disease and with liver disorders (secondary IgA nephropathy) have an increased risk. Chronic kidney failure can develop within 20 years of the onset of the disease (in 25-50% of patients).

Congenital Nephritis

- **Synonym:** Hereditary glomerulonephritis, Hereditary nephritis,
- this is a group of congenital diseases caused by mutations in GBM proteins,
- these include, for example, Alport syndrome.

Pathogenesis

There is a mutation in collagen IV (this type of collagen is found in the basement membranes, does not form fibrils or fibers, and is necessary for the normal function of the glomeruli, lens, and cochlea). The structure is a heterotrimer (chains $\alpha3$, $\alpha4$, $\alpha5$), mutation can occur in any of the monomers.

Morphology

The glomeruli appear normal until a late stage when secondary sclerosis may develop. The cells of the interstitium accumulate neutral lipids and glycosaminoglycans (mucopolysaccharides). With the gradual progression of the disease, glomerulosclerosis, vascular sclerosis, tubule atrophy and interstitial fibrosis increase. In the electron microscope, we observe irregular thickening of the GBM (but only in the late stages of the disease).

Clinical course

Inheritance can be X-linked (for $\alpha5$ gene defect), AD or AR (for $\alpha3$ or $\alpha4$ gene defect). Renal failure occurs between the ages of 20 and 50. There is hematuria and slowly progressive proteinuria.

Links

Related Articles

- Nephrotic syndrome
- Glomerulonephritis
- Alport syndrome

References

- KUMAR, Vinay – ABBAS, Abul K – FAUSTO, Nelson. *Robbins basic pathology*. 8. edition. Saunders/Elsevier, 2007. ISBN 978-1-4160-2973-1.