

# Musculus triceps brachii

## Beginning:

*caput longum* - *tuberculum infraglenoidale scapulae*;

*caput laterale* - posterior surface of the humerus, proximal to the *sulcus nervi radialis*;

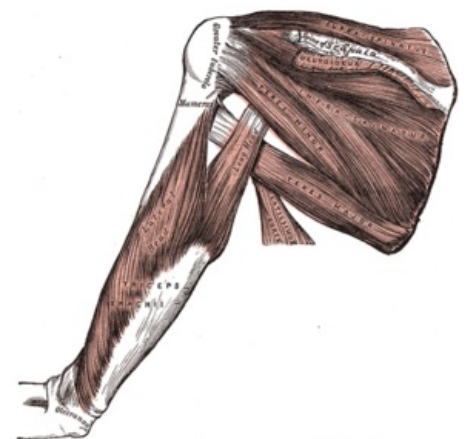
*caput mediale* - posterior surface of the humerus, distal to the *sulcus nervi radialis*.

**Tendon:** olecranon ulnae.

**Innervation:** *nervus radialis* (C6-C8).

**Function:** extension of the elbow joint; *caput longum* helps in dorsal flexion and adduction at the shoulder joint.

**Vascular supply:** *a. profunda brachii* (*caput longum*), *a. circumflexa humeri caudalis*, *a. subscapularis*, *a. collateralis radialis*, *a. circumflexa scapulae*, *a. collateralis ulnaris* (*caput mediale*).



Back muscles of arm.

## References

- ČIHÁK, Radomír. *Anatomie 1*. 2. vydání. Praha : Grada, 2001. 497 s. ISBN 80-7169-970-5.