

Musculus teres major

Beginning: *margo lateralis et angulus inferior scapulae.*

Tendon: *crista tuberculi minoris.*

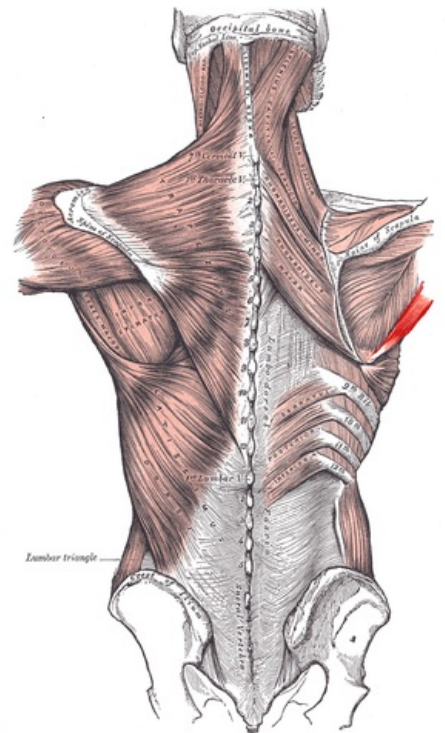
Innervation: *nervus subscapularis (C6).*

Function: internal rotation, auxiliary muscle in adduction of the arm.

Vascular supply: *a. subscapularis*

References

- ČIHÁK, Radomír a Miloš GRIM. *Anatomie*. 2., uprav. a dopl vydání. Praha : Grada Publishing, 2002. 470 s. sv. 1. ISBN 80-7169-970-5.



Posterior view of muscles connecting the upper extremity to the vertebral column.