

Musculus gluteus maximus

Origin: iliac blade (dorsal to *linea glutea posterior*), *os sacrum* , *os coccygis* , *fascia thoracolumbalis*, *crista iliaca (spina iliaca anterior superior)*, laterocaudal to attachment

Insertion: *tuberositas glutea*, *trochanter major femoris* , part of the bundles to the *tractus iliotibialis* .

Innervation: *n. gluteus inferior* (from L 4 –S 2).

Function:

1. hip joint – extension, external rotation, abduction (anterior bundle), adduction (posterior bundle);
2. knee joint – helps fix extension.

When standing upright it overlaps *the tuber ischiadicum* , when sitting it is outside it.

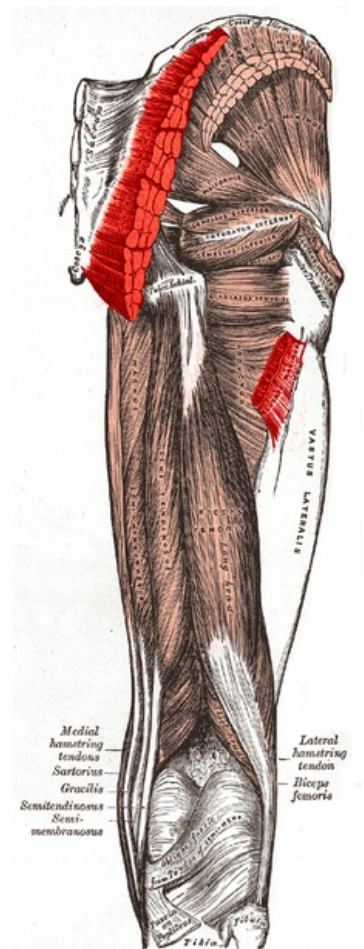
Links

Related articles

- Musculus gluteus minimus
- Musculus gluteus medius

References

- ČIHÁK, Radomír – GRIM, Miloš. *Anatomie*. 2., uprav. a dopl edition. Grada Publishing, 2002. 470 pp. vol. 1. ISBN 80-7169-970-5.
- VIGUÉ, Jordi. *Atlas lidského těla*. 3. edition. Rebo, 2007. ISBN 978-80-7234-881-7.



gluteus maximus muscle