

Musculus extensor indicis

Beginning: the back of the *ulna*.

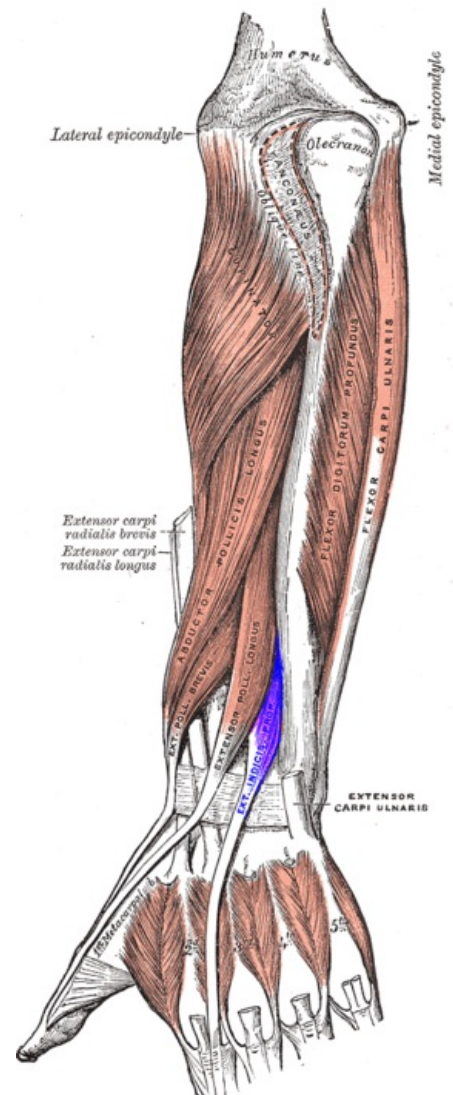
Limb: aponeurosis of the index finger (mostly distal article).

Innervation: *nervus radialis (ramus profundus)*.

Function: extense of the 2nd finger.

References

- ČIHÁK, Radomír. *Anatomie 1*. 2. vydání. Praha : Grada, 2001. 497 s. ISBN 80-7169-970-5.



Posterior surface of the forearm. Deep muscles. Extensor indicis muscle is labeled in purple.