

# Musculus abductor pollicis longus

## Beginning:

- back of the *ulna*,
- the back of the *radio*,
- *membrana interossea*.

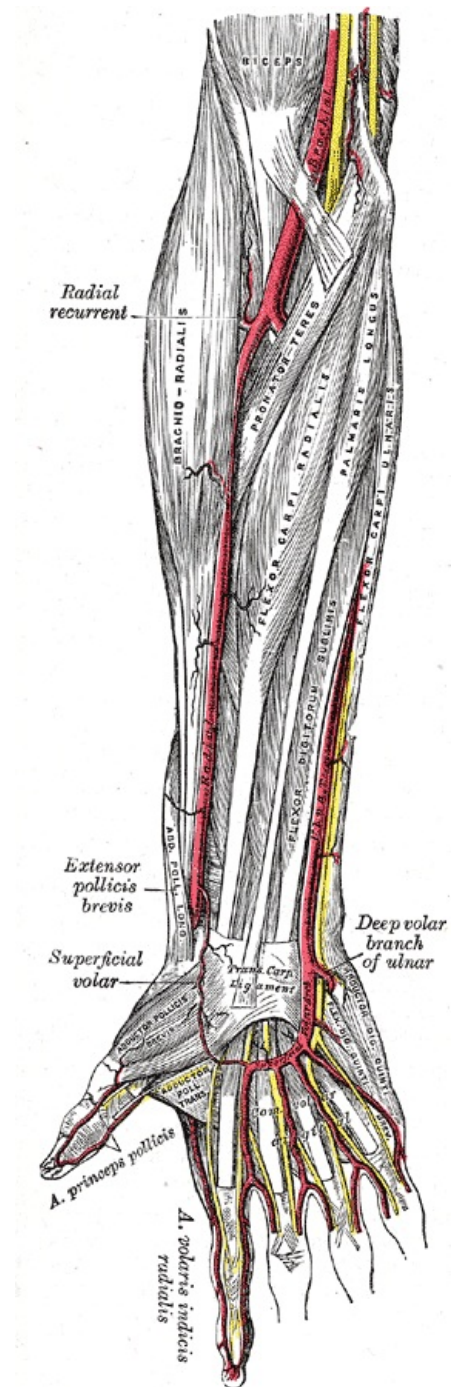
**Tendon:** base of thumb *metacarpus*.

**Innervation:** *nervus radialis (ramus profundus)*.

**Function:** abduction of the thumb.

## References

- ČIHÁK, Radomír. *Anatomie 1*. 2. vydání. Praha : Grada, 2001. 497 s. ISBN 80-7169-970-5.



The image shows some of the muscles and arteries of the right forearm and hand, including the superficial palmar arch (titled *Superficial Volar Arch* in this picture, which is an alternative term) and the common palmar digital arteries branching off of it. The unlabelled yellow lines are nerves. Palmar aspect with the proximal part (elbow) at the top and the distal part (hand) at the bottom. Unfortunately, the labels in the picture are not very legible because of the low resolution. To aid future improvements of the image, this is a list of all labels included in the image. Some of these terms are outdated/deprecated: Biceps [muscle] Brachial [artery] Radial recurrent [artery] Brachio-radialis [muscle] Pronator teres [muscle] Flexor carpi radialis [muscle] Palmaris longus [muscle] Flexor digitorum sublimis [muscle] Flexor carpi ulnaris [muscle] Radial [artery] Ulnar

[artery] Extensor pollicis brevis [muscle]  
Abductor pollicis longus [muscle]  
Superficial volar (arch) [artery] (the  
thinner and thicker parts of the arch are  
labelled separately; see below) Transverse  
carpal ligament Deep volar branch of  
ulnar [artery] Abductor pollicis brevis  
[muscle] Adductor pollicis transversus  
[muscle] Superficial volar arch [artery]  
(the thinner and thicker parts of the arch  
are labelled separately; see above) Flexor  
digiti quinti brevis [muscle] Abductor digiti  
quinti [muscle] Arteria princeps pollicis  
Common volar digital [arteries] Arteria  
volaris indicis radialis