

## Musculus abductor pollicis brevis

### Beginning:

- *tuberculum ossis scaphoidei*;
- *retinaculum musculorum flexorum*.

### Tendon:

- Base of proximal article of thumb;
- sesamoid bone of thumb (radial).

**Innervation:**

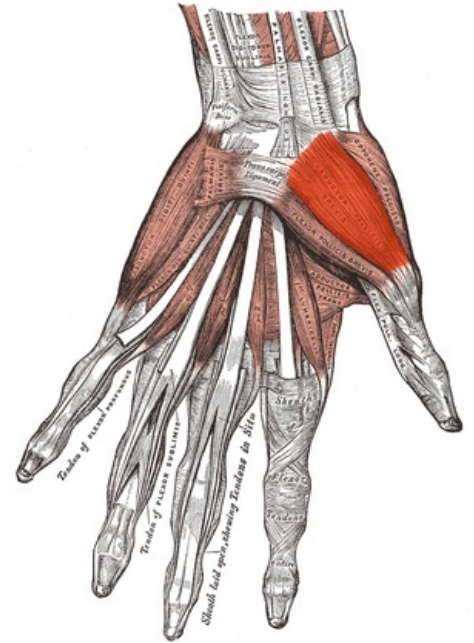
- *nervus medianus*.

**Function:**

- Abduction of the thumb (like the musculus abductor pollicis longus).

## References

- ČIHÁK, Radomír. *Anatomie 1*. 2. vydání. Praha : Grada, 2001. 497 s. ISBN 80-7169-970-5.



Musculus abductor pollicis brevis.