


Megaloblastic anemia

'Megaloblastic anemia is an anemia accompanied by the presence of large immature erythrocytes (**megaloblasts**) in the bone marrow (MCV > 95 fl, MCH often 40 pg and more). There is a reduced number of reticulocytes in the peripheral blood

Megaloblastic anemia:

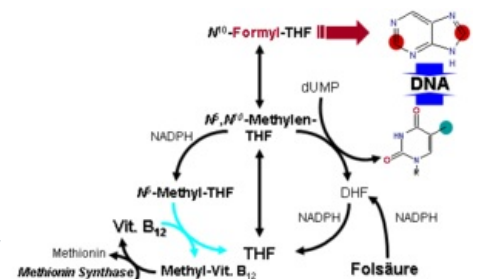


Template:Infobox - disease Template:Infobox - disease

Vitamin B12 deficiency anemia

Source: meat, milk, eggs.

In the body, it functions as a **coenzyme for the conversion of methyl-HF to THF'' with the simultaneous formation of methionine (important for choline synthesis) from homocysteine. This reaction also creates THF, which is subsequently methylated to methylene-THF. The latter is necessary for the conversion of dUMP to dTMP by thymidylate synthase, which is a key reaction for thymidine formation.** It also acts as a coenzyme of methylmalonyl-CoA mutase, which converts methylmalonyl-CoA to succinyl-CoA.



Vitamin B12 deficiency

It arises only after several years of reduced income. It is mainly manifested by changes in:

- **hematopoiesis** - Lack of dTTP for the synthesis of DNA leads to a slowing down of the division of (not only) precursors of erythrocytes. However, the formation of RNA and proteosynthesis are not affected (RNA contains uracil instead of thymidine) and so the blood cells form a normal amount of hemoglobin (a small amount of large erythrocytes). Defective erythrocytes die faster, sometimes already in the bone marrow (*inefficient erythropoiesis*). In the peripheral blood, there is at the same time "leukopenia" with macrocytosis and hypersegmentation of neutrophil nuclei and "thrombocytopenia". The bone marrow is hyperplastic. These manifestations can be suppressed by excessive intake of folic acid, which replaces the missing THF.
- **GIT** - leads to diarrhea.
- **Neuronech - axon demyelination**. The principle is the lack of methionine, which is necessary for the synthesis of choline and the phospholipid component of myelin sheaths. Methylmalonyl-CoA occurs in excess, from which defective lipids of the myelin sheath are formed. Affecting the posterior and lateral spinal cords, **funicular degeneration and peripheral neuropathy** are typical. Symptoms include **paresthesia, impairment of deep sensation**, rarely paresis.
- **Homocysteine level**, which is manifested by insufficient conversion of homocysteine to methionine. Homocysteine accumulates and is a risk factor for thrombosis.

 For more information see *Vitamin B12*.

Pernicious anemia

The most common form of megaloblastic anemia. Also called *Addison-Biermer disease*. It is an autoimmune disease in which *antibodies against parietal cells* are produced. This leads to atrophy of the gastric mucosa (gastritis type A) with achlorhydria.

Under normal circumstances, vitamin B12 binds to intrinsic factor in the stomach. This creates a complex that is resistant to digestive enzymes and is resorbed by enterocytes in the ileum.^[1] In patients with pernicious anemia, intrinsic factor is not produced, so vitamin B12 is not resorbed in the ileum and its deficiency occurs in the body.

Patients have an increased risk of **gastric cancer** as well as other autoimmune diseases (Hashimoto's thyroiditis, Addison's disease, DM AND).

Anemia due to folic acid deficiency (or active forms of tetrahydrofolate (THF))

'Source: **leafy greens, liver, meat**; The deficiency' **begins to manifest itself** after a few weeks to months.

Necessary for **synthesis of purine bases** (in the form of formyl-THF and methenyl-THF) and **thymidine**. During the formation of purines, it starts from the reaction of THF, while during the synthesis of thymidine, dihydrofolate (DHF) is formed. This must be reduced back to THF in order to be used again. This is ensured by the enzyme dihydrofolate reductase, which is blocked by methotrexate.

Folic acid deficiency


Affects:

- **hematopoiesis** - a picture similar to vitamin deficiency. B12.
- **GIT** - Hunter's glossitis, intestinal absorption disorders, diarrhea.

Distinguishing between folic acid deficiency anemia and vitamin B12 deficiency is done *using serum levels* of these substances.

 For more information see *folic acid*.

 For more information see *tetrahydrofolate*.



Price-Jones curve

Red = Hemolytic anemia (microcytes)

Green = normal

Blue = Pernicious anemia (macrocytes)

Causes of megaloblastic anemias

Insufficient income

Risk especially for vegans and people in developing countries.

Insufficient absorption

Intrinsic factor deficiency - antibodies against parietal cells of the stomach or an internal factor possibly arises after gastrectomy.

Nutrient malabsorption - celiac disease, Crohn's disease, ulcerative colitis.

Intestinal resection - folic acid is absorbed mainly in the duodenum and upper jejunum, vitamin B12 in the ileum.

Colonization of the small intestine by bacteria - they utilize vitamin B12. A predisposition is intestinal stump after GIT operations (so-called dead end syndrome) or stenosis.

Tapeworm infection - utilizes vitamin B12.

Deficiency of enzymes important for the absorption of vit. B12 - hereditary disease.

Increased consumption - pregnancy, growth.

Increased losses - dialysis.

Cytostatics - methotrexate, purine analogues (mercaptopurine), pyrimidine analogues (5-fluorouracil, cytarabine).

Diff. dg.: Macrocytic anemia can also be found in **alcoholics**, **liver diseases** and **hypothyroidism**. Here, however, megaloblasts in the bone marrow are missing.

Links

Related Articles

- Anemia
- Folic acid
- Folate metabolism disorders
- Vitamin B12
- Cobalamin metabolism disorders

References

- ws:Megaloblastová anémie
- PAVEL, Klener, et al. *Internal Medicine*. 4. edition. Prague : Galen, 2011. 1174 pp. ISBN 978-80-7262-857-5.

- CZECH, Richard, et al. *Intern.* 1. edition. Prague : Triton, 2010. 855 pp. ISBN 978-80-7387-423-0.
- KUMAR, Vinay – ABBAS, Abul K – FAUSTO, Nelson, et al. *Robbins Basic Pathology*. 8. edition. Philadelphia : Saunders/Elsevier, 2007. 946 pp. ISBN 978-1-4160-2973-1.
- NETIME, Emanuel, et al. *Pathological physiology of organ systems : Part I*. 1. edition. Prague : Karolinum, 2007. ISBN 978-80-246-0675-0.
- MARTINKA, Ivan. Neurological manifestations of vitamin B12 deficiency. *Neurology for practice* [online]. 2013, y. 14, vol. 6, p. 287-291, Available from <http://www.neurologiepropraxi.cz/artkey/neu-201306-0004_Neurologicke_prejavy_deficitu_vitaminu_B12.php>. ISSN 1803-5280.

References

1. JIRÁSEK, Václav – BRODANOVÁ, Mary – MARECEK, Zdeněk. *Gastroenterology, Hepatology*. 1. edition. Prague : Galen, 2002. ISBN 80-7262-139-4.

Template:Navbox - blood disease