

# Mediastinitis

## Acute mediastinitis

**Acute mediastinitis** is a serious disease with a high lethality (approximately 50%).

- Usually a consequence of perforation of the oesophagus (endoscopic procedures, tumours), rarely a complication of pneumonia/mediastinitis (possibly lung abscess, empyema) or even as a complication of coemphysitis.

### Clinical picture

- Fever with retrosternal pain,
- with esophageal perforation dysphagia + subcutaneous emphysema,
- X-ray: enlargement of the mediastinum, ev. with pleural effusion + mediastinal emphysema.

### Therapy

- ATB i.v., mediastinal drainage.}

## Chronic mediastinitis

**Chronic mediastinal inflammation** is a granulomatous, fibrous process of mostly unclear etiology. The occurrence of this disease is rare.

- *Ormond's disease* = idiopathic mediastinal fibrosis + retroperitoneal fibrosis.

### Clinical picture

- At the beginning without difficulty,
- later upper vena cava syndrome, esophageal stenosis + tracheobronchial tree stenosis,
- X-ray: enlargement of the upper mediastinum, rarely calcification.

### Therapy

- Surgical removal of mechanical compression, glucocorticoids.

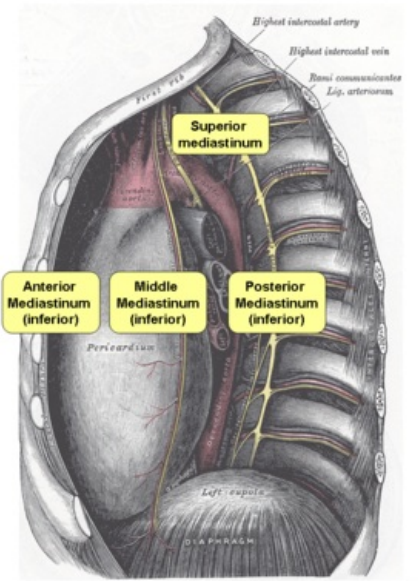
## Links

### Related Articles

- Mediastinum

### Bibliography

- DÍŤĚ, Petr. *Vnitřní lékařství*. 2. edition. 2007. ISBN 978-80-7262-496-6.



Anatomy of the mediastinum