

## Local Anaesthesia and Sedation (Dentistry)

Anesthetics = substances that interrupt the conduction of painful excitement through a sensitive nerve. Anesthesia in the area of teeth, gums and oral cavity is a common procedure in the dental office. Its successful and rapid execution depends on a detailed knowledge of the spatial arrangement of the anatomical structures that are the subject of anesthesia, and every dentist must master them.

## Local anesthesia

Removal of soreness at the site of surgery.

## Surface anesthesia

This is the simplest method of local anesthesia, the anesthetic is applied to the surface of the mucous membrane and from there it diffuses into the *lamina propria mucosae* and into the *submucosa*, where it acts on the nerve endings. Use, for example, to numb the mucous membrane before injection.

- **Solution form** - MEZOCAIN 4%, NUPERCAIN, XYLOCAIN spr 10%, XYLESTEZIN spr 15%, XYLONOR spr 15%, GINGICAIN;
- **Gel form** - XYLONOR gel 5%.

### Infiltration anesthesia (terminal)

Anesthesia is injected into the tissue, where the terminal branches of the sensitive nerves are numbed. Anesthetic seeps through the cancellous bone surrounding the alveoli. The purpose is to anesthetize the final branches of the dental plexus. The application is usually performed submucosally (under the gingiva), suprapariosteally (above the periosteum) and rarely intraparadontally ( *intraalveolar anesthesia* = pressure application of a small amount of anesthetic (about 0.3–0.4 ml) to the peridontia region, numbing only the tooth in question, it is better tolerated by the patient than seductive application, as the patient does not have an unpleasantly insensitive entire jaw for several hours ), **intraalveolarly** (the anesthetic is administered into the dental pulp, this is a less used method of infiltration anesthesia) or **intraosseously** ( local anesthetic is deposited through the trepanation hole in the compact into the bone).

### Technique of infiltration (terminal) anesthesia

With our fingers or a dental mirror, we lift the lip, thereby stretching the temporary eyelash. Then we insert the needle about 1 cm above the immobile gingiva. The needle passes through the mucosa, through the submucosa, over the periosteum. The needle hole must be facing the bone to avoid damaging the periosteum with the needle tip. We deposit about 0.3 ml of anesthetic. Next, move the needle apically, apply 1-1.5 ml of anesthetic in the area of the tip of the root. The rest (0.3 ml of anesthetic) is applied palatally about 1 cm above the edge of the gingiva, where the processus alveolaris passes into the palatum durum. When applying infiltration anesthesia to the second and third upper molars, we proceed similarly to anesthesia on the tuber maxillae, i.e. we perform aspiration before injecting the anesthetic, as the pterygoid plexus may be impaled. We use infiltration anesthesia mainly in the upper jaw and in the frontal section of the lower jaw.

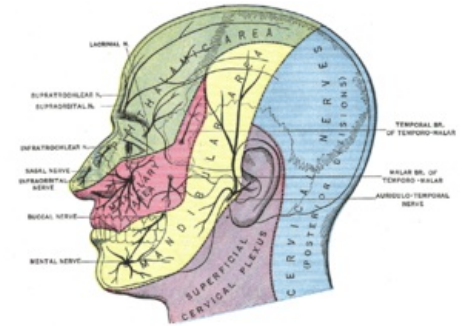
## Anatomy of the innervation of the maxilla

Mediated by the branching of the ``nervus maxillaris – 2nd branch of the trigeminal nerve. Of its three main branches, the most important for the dentist are the infraorbital nerve and the pterygopalatine nerve (the third branch, the zygomatic nerve, is not essential for the needs of local anesthesia).

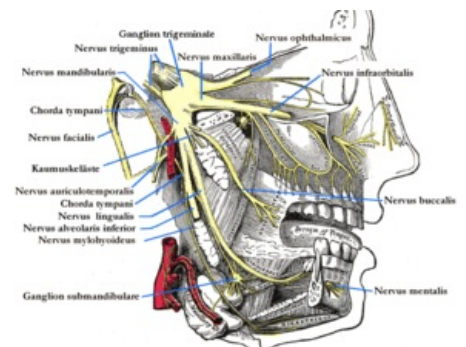
- Nervus infraorbitalis – from the nervus infraorbitalis depart the "nervi alveolares superiores", which are further divided into branches innervating the alveolar processes of the upper jaw:
  - *rami alveolares superiores posteriores* – innervates the molar region;
  - *ramus alveolaris superior medius* – innervates the middle and frontal area;
  - "rami alveolares superiores anteriores" - innervate the area of canines and incisors.
- Nervi pterygopalatini – two to three short branches departing from the "nervus maxillaris", which enter the "ganglion pterygopalatinum", pass through it and then give off a number of branches.

The inner region of the palatal processes of the maxilla (*processus palatinus maxillae*) is innervated by three branches:

- nervi palatini majores;



### Innervation areas of individual branches of the trigeminal nerve



Individual nerves of the 2nd and 3rd branches of the trigeminal nerve

- minor palatine nerves;
- nasopalatine nerve.

## Anatomy of mandibular innervation

The innervation of the lower jaw is mediated by the branches of the *nervus mandibularis* - the 3rd branch of the trigeminal nerve. Of its five main branches, the most important for the dentist from the point of view of local anesthesia are:

- inferior alveolar nerve;
- lingual nerve;
- buccal nerve.

## Regional (seductive) anesthesia

- Numbness of the region of a certain nerve branch.

Applying anesthetic to the course of the nerve branch interrupts the supply of impulses from the landscape, innervated by this branch. It is applied to the points of entry of the trigeminal into the bony canals in the maxilla and mandible or to the places of exit from these canals. Nerve fibers accompany the vessels, so it is necessary to aspirate before application.

### Maxilla

- on tuber maxillae (nn. alveolares superiores posteriores);
- at the foramen infraorbitale (to canalis infraorbitalis – n. infraorbitalis, nn. Alveolares superiores medii et anteriores);
- at foramen palatinum majus (n. palatinus);
- for foramen incisivum (n. nasopalatinus).

### Mandible

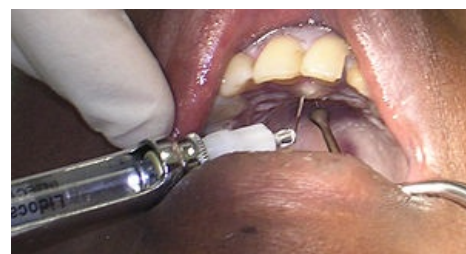- at the foramen mandibulae (n. alveolaris inferior);
- at foramen mentale (to canalis mentalis – n. mentalis).

Anesthesia for the foramen mandibulae is most often used:

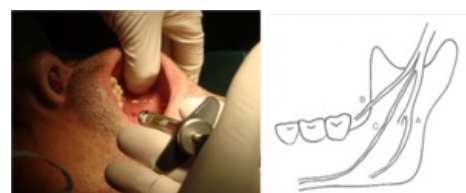
- directly – more pleasant for the patient;
- indirectly – more accurate, but risk of periosteum injury.

### Technique of direct mandibular anesthesia

I find the injection site in a plane about 1 cm above the occlusal surfaces of the lower molars (by placing the index finger on the chewing surfaces of the molars). With the tip of my finger, I simultaneously feel the front edge of the branch of the mandible, namely its outer (linea obliqua) or inner edge (crista temporalis). Medially from the crista temporalis, the ligamentum sphenomandibulare runs upwards and, when the mouth is open, picks up the mucous membrane in the eyelid, where the fossa lies. I direct the syringe with the needle from the area of the premolars of the opposite side, the needle penetrates the mucosa in the alveolus and touches the surface of the bone in the sulcus coli mandibulae at a depth of about 2 cm. I aspirate with a syringe and, if blood is not sucked in, I apply 1–1.5 ml of anesthetic.



Anesthesia on forum. incisive



Anesthesia of inferior alveolar nerve

## Trunk Anesthesia

Anesthesia of the maxillaris (foramen rotundum) or mandibularis (foramen ovale) is performed during major surgical procedures in the orofacial area.

## Links

### Related Articles

- Anesthetics (Dentistry)
- Anesthetics/Complications
- Trigeminal Nerve
- Mandibular anesthesia
- Anesthesia at tuber maxillae
- Anesthesia for foramen palatinum majus
- Anesthesia at the foramen mentale
- Anesthesia at the infraorbital foramen
- Anesthesia for foramen incisivum

## External links

- Template:Acute

## References

- FREEDOM, Otto. *Dental propaedeutics : Textbook for Medical Faculties*. 1. edition. Avicenum, 1984. 392 pp.
- TOMAN, Jaroslav. *Stomatologická chirurgie*. 1. edition. 1984.