

# Lateral Neck Region, Scalenic Fissure

## Lateral Neck Region

Consists of 2 triangles, Occipital (Omotrapezoid) and Supraclavicular (Omoclavicular) triangles. This region is known as the Posterior Triangle:

Borders:

- Anterior - m. sternocleidomastoideus
- Posterior - m. trapezius
- Inferior - clavicle

### Occipital (Omotrapezoid) Triangle

Borders:

- Anterior - m. sternocleidomastoideus
- Posterior - m. trapezius
- Inferior - Inferior belly of m. omohyoideus

Contents:

- Cranial Nerve 11 (Accessory nerve)
- Branches of cervical plexus (erb's point)
- Supraclavicular brachial plexus

### Supraclavicular (Omoclavicular) Triangle

Borders:

- Superior - Inferior belly of m. omohyoideus
- Anterior - Posterior margin of m. sternocleidomastoideus
- Inferior - clavicle

Contents:

- Subclavian artery
- External jugular vein
- Brachial plexus
- Phrenic nerve

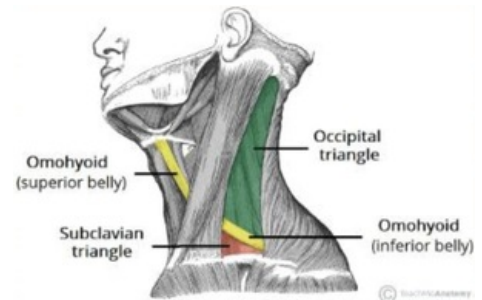
## Scalenic Fissure

Borders:

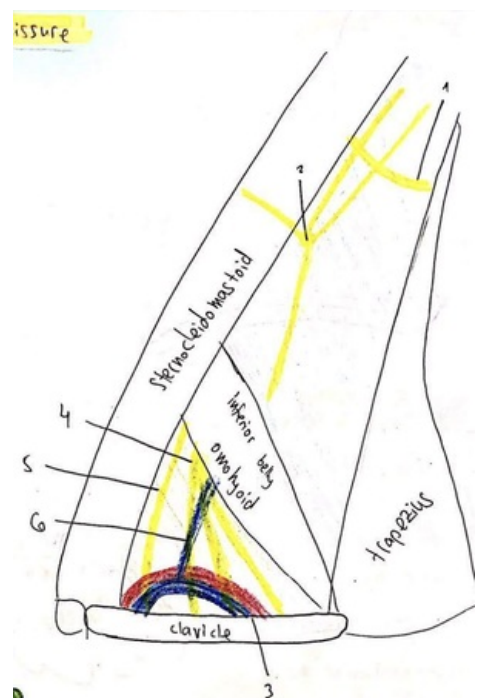
- Anterior - Anterior scalene muscle
- Posterior - Middle scalene
- Inferior - 1st rib

Contents:

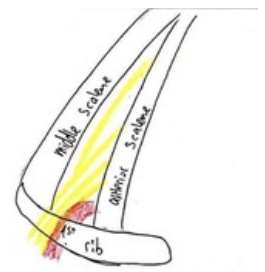- Brachial Plexus
- Subclavian Artery



Posterior Triangle of the Neck



Posterior Triangle of the Neck (schematic). 1 - CN XI; 2 - erb's point; 3 - Subclavian artery and vein; 4 - brachial plexus; 5 - phrenic nerve; 6 - external jugular vein



Scalenic fissure (schematic) - note the position of the brachial plexus (yellow)