

# Juvenile idiopathic arthritis

**Juvenile idiopathic arthritis** or **juvenile rheumatoid arthritis** is *the most common systemic disease in children age*. This disease begins before the 16th year of age and must last more than 6 weeks. The classifications of pediatric arthritis are different. The most recent is the so-called ILAR classification → JIA. Others are: systemic, oligoarthritis, polyarthritis, psoriatic arthritis, arthritis with enthesitis and other arthritis. Most often, the knees and other **large joints**.

## Epidemiology

This is a common disease, which **incidence** is 2-20/100,000. **Girls** tend to be affected 2-3 times more often than **boys**. Juvenile idiopathic arthritis has its two peaks – up to 3 years of age and in puberty.

## Etiology and pathogenesis

The disease is quite unknown, probably multifactorial. There are 2 main **theories**. Either it is an **autoimmune disease**, which is characterized by abnormal T-lymphocytes synovialitis. It is explained by immunogenetic influences that affect antigenic presentation (APC) a T-bb, thereby changing the course of the disease. The second option is the so-called genetic predisposition, where part of the short shoulder strap 6th chromosome, where HLA system is located, has a controlling role.

*Other factors* are stress, hormonal dysbalance, infection (mycoplasma, EBV) or dysregulation of ANS.

## Pathological-anatomical picture of joint involvement

There is sedation and hypertrophy of the synovial lining → **pannus** (granulation tissue formed by fibroblasts, blood vessels, round cell infiltration). Blood vessels are clogged with inflammatory cells and perivascular infiltrates are formed in them. Virgo grows from the osteocardiagnotic junction to the cartilage of the articular surfaces and destroys them. Erosion occurs only to possible defects. There is a disability of the subchondral bone with the formation of **cysts ischemization** on the basis of vascular impairment. **Deformities** of the articular ends of articulative bones are formed. The same process proceeds periarticularly and leads to the usuration of ligament and joint capsule, which causes stability of the joint.

**Synovial biopsy** is hypertrophy and hyperplasia stratum synoviale, subsynovial layer is overlapped and edematous, vascular hyperplasia occurs with infiltration of **T-lymphocytes and plasmocytes**.

## Clinical picture

### Oligoarthritis

Oligoarthritis is an inflammatory disability of low intensity in 4 or fewer joints. Extraarticular manifestations are rare (except for chronic uveitis). Mainly the lower limbs are affected, in 60% it is the knees, then the malleolus, or the elbow. The affected joints tend to be swollen, warmer, minimally painful, there is a pronounced restriction of joint movement (often morning stiffness). The **prognosis** is usually good.

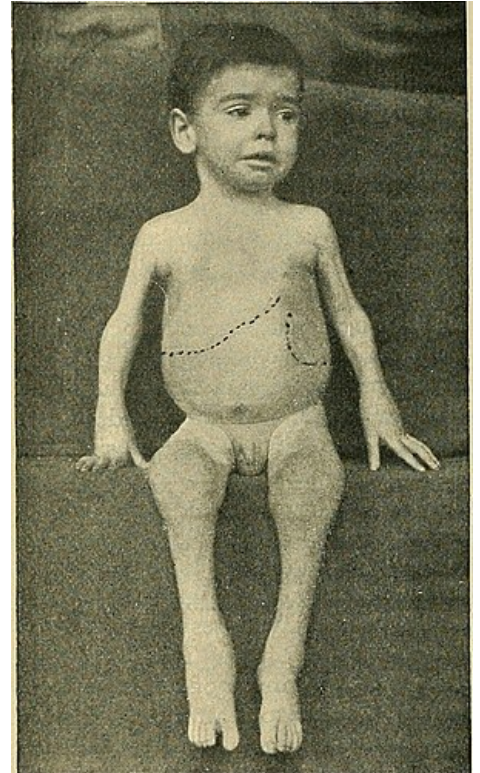
### Extended oligoarthritis

After the first 6 months, the disease affects 5 or more joints. The image and prognosis are close to polyarthritis. However, the formation of flexion contractures and joint deformities is more common.

### Polyarthritis

- According to the immunological evidence of rheumatoid factor (antiglobulin antibody) in serum, we divide it into:
  1. **polyarthritis RF-negative** (seronegative);
  2. **polyarthritis RF-positive** (seropositive).

The beginning is mostly gradual, affecting more than 5 joints (mostly more than 8<sup>[1]</sup>) arthritis can be both remittent and persistent with a tendency to symmetrical disability mainly of **large joints** (knees, wrists, elbows, hips), hip joints tend to be affected in 1/2 cases. Often there are diseases of the cervical spine and temporomandibular



Juvenile idiopathic arthritis

jointing. In small joints of the hand, it is a disease mainly of the interphalangeal joint of the thumb, 2nd and 3rd MCP of joints, proximal interphalangeal joints of all fingers. They are hot, soaked, rarely reddened. Deformities are divided into: type of **buttonhole** (boutonnière, PIP flexion and DIP joint hyperextension), where there is flexion contraction of the fingers and type of **swan neck** (swan-neck, PIP hyperextension + DIP joint flexion).

**Extraarticular impairment** includes subcutaneous rheumatic nodes, hepatosplenomegaly and lymphadenopathy. **Seropositive polyarthritis** tends to be significantly destructive, corresponds to RA in adults, in **seronegative polyarthritis** we note a milder course, when it can even go into permanent remission.

## Systemic form of JIA (Still's disease)

Still's disease is a severe systemic disability at the beginning of JIA in 10% of children. There is fever (briefly exceeding 39 °C), tachycardia, macular exanthema around the torso and upper extremities, hepatosplenomegaly, generalized lymphadenopathy and pericarditis.

Joint injuries are most often affected by large limb joints and small joints of the hand. It is important not to forget to examine ATM and the range of movement of the cervical spine (subluxation at the atlantooccipital and atlantoaxial levels with compression of nerve structures).

**Extraarticular symptoms** include: *abnormalities of growth and general development of the child, local growth disorders and chronic uveitis*. Approximately 1/2 of patients experience calming and the next course is under the image of oligoarthritis, in 2nd 1/2 there is progression and severe joint involvement.

## Arthritis with entesitis (spondyloarthropathy)

Spondyloarthropathy begins mostly with soft tissue disabilities, especially tendon tendrites around the joints.

**SEA syndrome** is a myoskeletal disease with the beginning of 16 years of life, seronegativity on RF and ANA, entezitis and arthritis/arthritis are mostly found outside the axial skeleton.

**Juvenile ankylosing spondylitis (JAS)** is a chronic inflammatory disease of peripheral and axial joints, often associated with entesitis, seronegativity on RF + ANA, a significant proportion of heredity.

**Etiology and pathogenesis:** the onset of symptoms occurs in late childhood and adolescence, 7 × more often boys are affected, there is a close link with the antigen HLA-B27 which is the trigger for intestinal infection. **Clinical picture:** Arthritis of peripheral joints appears at the initial stage – mainly in the lower extremities and entezitis – discrete swelling, soreness, inflammatory affection of SI joints (X-ray: diffuse osteoporosis of the surroundings, blurring of the boundary of the subchondral bone, erosion → and expansion of the joint slit → the demise of the joint slit and sacroiliac fusion), changes in the spine, calcification of the lig. longitudinale anterior, later vertebral synostosis under the image of the "bamboo rod".

## Psoriatic arthritis

This is arthritis with psoriasis. The disease is characterized by dactylitis – prst je tvaru buřtíku, tzv. „sausage digit“) the finger is the shape of a sausage digit and nail abnormalities, we observe dimming and transverse striations. The disease occurs mainly in **girls** of preschool age and around 10 years of age. Most often, the knee and small joints of the hand and foot (typically asymmetrically) are affected. **The prognosis** is worse compared to other forms of JIA.

## Characteristics of clinical manifestations

- **arthritis** – sore joint with restriction of movement, soreness, stiffening, which does not originate in mechanical impairment. The effusion should have a typical cytological finding;
- **fever** – at least two weeks of bouncy fever per day with a temperature peak above 39 °C and a return below 37 °C;
- **serositis** – pericarditis, pleuritis, peritonitis;
- **entezitis** – suffocation and soreness at the site of the tendral;
- **psoriatic rash** – to be confirmed by a dermatologist;
- **dactylitis** – swelling of the fingers, which extends beyond the edge of the joint (resembles a sausage);
- **rheumatoid factor positivity, positive Autoantibodies** – 2 positive findings are required at an interval of 3 months;
- **uveitida** (rheumatoid eye involvement) – it must be confirmed by an ophthalmologist by examination with a slotted lamp;
- **remise** – no joint manifestations or pain, normal FW during 2 years without treatment;
- **relaps** – return of symptoms after a resting period of at least 6 months.

## Diagnosis

Based on diagnostic criteria, of which there are a number of:

- **1. JIA diagnostic criteria:**

The disease begins to manifest itself before the 16th year. The patient suffers from arthritis of one or more joints, swelling, effusion, the presence of restriction of movement, stiffness in movement, warmer joint. Arthritis lasts 6 weeks or more. During the first 6 months, the disease proceeds as polyarthritis, oligoarthritis or systemic form. It is important to exclude other forms of juvenile arthritis.

## ■ 2. clinical criteria:

Arthritis lasting 3 months or more. Arthritis of the next joint is 3 months. Later, there is a symmetrical disability of small joints, effusions in the joint, contracture in the joint, tendosynovitis or bursitis, muscle hypotrophy and atrophy, stiffness in the joint, rheumatoid eye involvement and rheumatoid nodules.

## ■ 3. X-ray criteria:

X-ray reveals osteoporosis, microcysts, narrowing of joint slits, bone growth disorders and cervical spine involvement.

## ■ 4. laboratory criteria:

Positive histological evidence from synovial tissue appears. The **blood count** shows signs of inflammation. Active JIA has increased ferritin, leukocytosis, thrombocytosis, increased sedimentation. Chronic course shows normocytic anemia. **Immunological testing** shows Autoimmunity disease (mainly IgGpos. – high risk of chronic uveitis in girls with oligoarthritis, negat. – arthritis with enthesopathy), positive rheumatoid factor (antiglobulin antibodies to Fc fragment IgG, seropositivity (latex test) indicates heavier course), HLA-B27 (genetically determined surface antigen hl. leukocytes, in most patients with ankyloid spondylite).

## Conclusion

If the patient has 4 of the listed manifestations with proven arthritis, we are talking about a **certain JIA**. If there are 8 or more criteria – **classic JIA**.

In outpatient practice, this can not be done, if a rheumatic disease is suspected, we send the child to a pediatric rheumatologist.

## Imaging examination in JIA

- **X-Ray** (early signs : swelling of periarticular soft tissues and joint culling, late : periarticular osteoporosis, reduction of joint crevices, bone erosion, acceleration of epiphysal mingling with an early closure of the growth plate and short circuit of the bone, hypertrophic ends of long bones);
- **sonography** (quantification of joint effusion in the hip joint);
- **MRI** (on-the-shoulder erosion of articular cartilage, suspected necrosis of the femur head in the chronic course of arthritis, planning of synectomy);
- scintigraphy, diagnostic arthroscopy, synovial biopsy.

## Pharmacological therapy

It can accompany rehabilitation, spa therapy, regime measures, psychosocial care or rheumatoid and prosthetic care.

## Nonsteroidal antirheumatics

The goal of therapy is to find a drug blocking more COX-2 (inflammation) than COX-1 (stomach, kidneys, platelets). Selective COX-2 are expensive, but reduce THE (gastropathy, interstic nephritis, papillary necrosis, bleeding conditions, bronchospasm, etc.). The practitioner can indicate the treatment himself, usually doing so only after consulting a specialist. Therapy takes at least 6 weeks to evaluate the results. The most commonly used therapy is an indication of **ibuprofen**, KO, liver tests and urine are monitored. **Diclofenac**, **tiaprofenic acid** and **indomethacin**, also indicated, but indomethacin is not served for more than 3 weeks.

## The second row of antirheumatics

The second row of antirheumatics are slow-acting antirheumatics. About 2/3 of children with JIA do not respond to NSA treatment, so we usually serve this group with nsaid.

These include:

- **Methothrexate** – a competitive dihydrofolate ductase inhibitor, leads to a decrease in the supply of pyrimidines a purines to rapidly dividing cells, has an antitumor effect, reduces the activities of neutrophils, lymphocytes a macrophagi. The next day we will pass the folic acid. Methotrexate is relatively safe in low doses, it is served orally (possible i.m., s.c.). Side effects – mucosal ulceration, liver damage, changes in blood count.
- **Sulfasalazine** – among others it is used for non-specific intestinal inflammations. Side effects – skin manifestations, mood swings, hepatotoxicity, ko changes. The effect occurs at least in 2-3 months of administration.
- **Antimalarials** – **hydrochloroquine** (immunomodulation, collagenase inhibition), Side effects – hyperpigmentation, corneal and retinal changes.

## DMARDs

- (Disease-modifying antirheumatic drugs, called basal drugs) – therapies for active synovialitis if NSAIDs are not enough, have an anti-inflammatory effect by reducing cytokine production in the weeks to months after deployment.

## Corticosteroids

Indications of corticosteroids must be very responsible, the doctor must be aware of the possible consequences. It is administered topically (intraarticularly – an essential element of early-stage treatment), orally and parenterally. An absolute indication is a systemic form with life-threatening pericarditis and a severe form of uveitis.

## Surgical therapy

Rheumatology, unlike adults, is used less frequently in children. **Synectomy** is the so-called extirpation of the inflammatory lining of the joint. The procedures on **soft tissues** that are performed are called **tenotomies** and **capsulotomy**. Performances on the skeleton are usually operations that deal with unequal limb lengths after irritating overgrowth of long bones.

## Prognosis

Mortality in JIA is below 1%, persistent arthritis activity occurs in 31-55% of patients, severe functional impairment in 9-30%.

## Evaluation of disease

1. **active** (the number of joints with active synovialitis unresponsive to therapy increases);
2. "**stabile** (*stable number of joints, corresponding to therapy*);
3. **inactive** (no signs of active synovialitis/active extraarticular manifestations);
4. **remission** (no signs of active synovialitis of joints, non-joint manifestations, 2 years or more without treatment).

## Evaluation of the functional activity of the patient

We divide it into two ratings: according to **Steinbrocker** and modified score according to **Lysholm**.

## Links

### Related articles

- **Revmatologie:** Henoch-Schönlein purpura ■ Kawasaki disease ■ systemic lupus erythematoses ■ Juvenile dermatomyositis ■ Juvenile idiopathic arthritis ■ Rheumatoid arthritis ■ Psoriatic arthritis ■ Ankylosing spondylarthritis

### Literature used

- DUNGL, P.. *Ortopedie*. 1. edition. Praha : Grada Publishing, 2005. ISBN 80-247-0550-8.
- BENEŠ, Jiří. *Studijní materiály* [online]. ©2007. [cit. 2010]. <<http://jirben.wz.cz>>.
- HRODEK, Otto – VAVŘINEC, Jan. *Pediatric*. 1. edition. Praha : Galén, 2002. ISBN 80-7262-178-5.
- ŠAŠINKA, Miroslav – ŠAGÁT, Tibor – KOVÁCS, László. *Pediatric*. 2. edition. Bratislava : Herba, 2007. ISBN 978-80-89171-49-1.
- 1. MUNTAU, Ania. *Intensivkurs Pädiatrie*. - edition. Elsevier, Urban & Fischer, 2011. 574 pp. ISBN 9783437433931.