

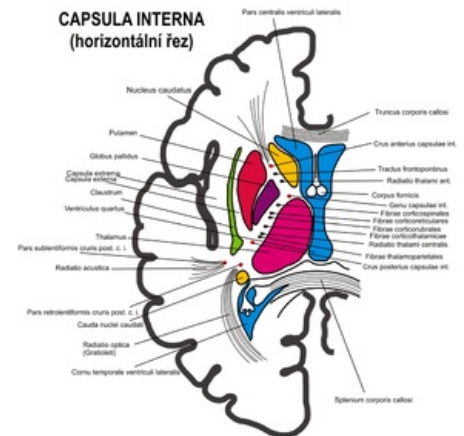
Internal capsule

The **internal capsule** descends from the center semiovale between the thalamus and basal ganglia.

- leads most cortical centripetal and centrifugal fibers
- in the horizontal section it has the shape of an externally open V - between the arms there is ncl. lentiformis (putamen + globus pallidus)

Description

- **crus anterius** - *anterior arm between caput nuclei caudati and ncl. lentiformis* - tr. fronto-pontinus
- **gene** - *knee* - tractus corticonuclearis (for facial muscles)
- **crus posterius** - *posterior arm between thalamus a ncl. lentiformis* - corticospinal tract (for limb and torso muscles), tr. cortico-rubralis, tr. cortico-reticularis
- **pars retrolenticularis** - enlarged part dorsally from ncl. lentiformis - tr. parieto-occipito-pontinus, radiatio optica a austica (end of the visual and auditory pathway)
 - *in the crus anterius + gene + crus posterius the fibers connecting the thalamus and the cortex run - radiatio thalami anterior, superior et posterior*
 - *capsula externa (between putamen and claustrum) and capsula extrema (between claustrum and insular cortex) extend from the internal capsule*
 - during bleeding in the area of the internal capsule - the diagnosis is determined according to the typical symptoms of damage to individual pathways



Horizontal section of the internal capsule

Links

Related articles

- Motor system
- Bleeding into the internal capsule

References

- ws:Capsula interna
-