

Infrapiriform Foramen

English: *Infrapiriform foramen*

Latin: *Foramen infrapiriforme*



The **infrapiriform foramen** (lat. *foramen infrapiriforme*) is bounded by **piriform muscle** (*musculus piriformis*), **greater sciatic notch** (*incisura ischiadica major ossis coxae*), **sacrotuberous ligament** (*ligamentum sacrotuberale*) and **sacrospinous ligament** (*ligamentum sacrospinale*). It is a part of the greater sciatic foramen (*foramen ischiadicum majus*). It contains:

- inferior gluteal nerve
- inferior gluteal vessels
- pudendal nerve
- internal pudendal vessels
- sciatic nerve
- posterior femoral cutaneous nerve

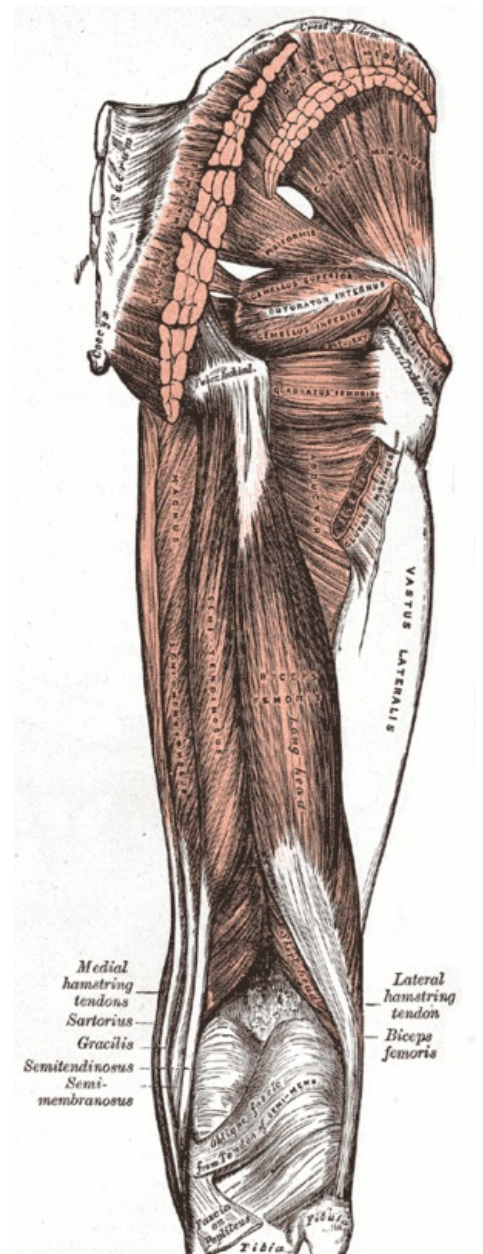
Links

Related articles

- Suprapiriform Foramen

Bibliography

- PETROVICKY, Pavel, et al. *Anatomie s topografií a klinickými aplikacemi : Sv. 1, Pohybové ústrojí*. 1. edition. Martin : Osveta, 2001. 463 pp. ISBN 80-8063-046-1.



Foramen infrapiriforme