

Hypertrophy

Hypertrophy (together with hyperplasia) belongs to **progressive changes**. It occurs with increased functional demands on the tissue. Hypertrophy is significant due to its *mechanical effect* on the surrounding organs (enlarged thyroid gland – oppression of the airways and carotids, enlarged prostate – oppression of the urethra) and *similarity to tumors* (pseudotumors), hypertrophy of the heart is very significant during circulatory failure.

Definition: enlargement of cells and organs, occurs in tissues with limited mitotic activity (heart, muscles).

Hypertrophic tissue works **energy-defficiently**, its performance per mass unit is lower than that of normal tissue, and more waste substances are also produced during its activity (e.g. waste products of purine metabolism)).

Work-caused

It occurs during long-term work load, e.g. skeletal muscle in athletes. This also includes *compensatory hypertrophy*, such as hypertrophy (concentric, later eccentric) of the heart chamber in hypertension in large (*cor hypertonicum*) or small (*cor pulmonale*) circulation, valvular defects, etc., or trabecular hypertrophy of the urinary bladder in the case of obstruction of the urethra by hyperplastic prostate or thickening of the intestinal muscle above the stenosis..

Nervously conditioned

It arises when the innervation of some sections of the GIT (cardia and lower part of the esophagus, rectum and ace-shaped colon) is disturbed, which leads to spasm (permanent contraction of the muscle due to the impossibility of relaxation) and its hypertrophy, the section orally from the narrowed part expands with accumulated contents, often in this expanded section, the muscle still hypertrophies in a compensatory way, examples are achalasia of the esophagus,, Hirschprung's disease (megacolon congenitum) and pyloric stenosis.

Hormonally conditioned

It is usually hyperplasia:

- physiologically in women in the uterus and mammary gland during pregnancy,
- in men hyperplasia of the prostate,
- hyperplastic goiter,,
- acromegaly (hypertrophy and hyperplasia of the end parts of the skeleton due to increased production of somatotrophic hormone in the pituitary gland),
- gynecomastia (hyperplasia of the mammary gland in men, e.g. with an excess of estrogens).

Vascular

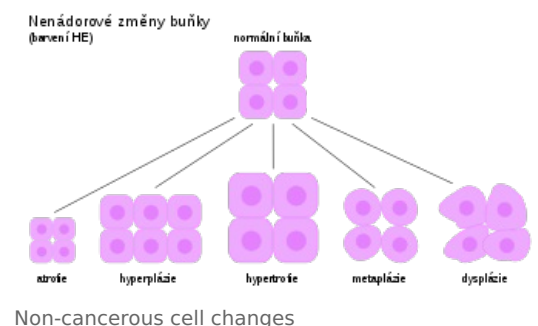
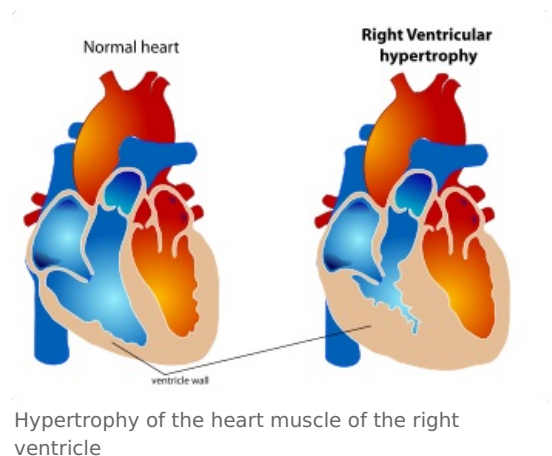
It can be post-inflammatory hypertrophy of the epithelium (increased blood flow to the inflamed tissue) or gigantomelia (enlargement of the limb due to congenital arteriovenous shunts that significantly increase blood flow in the affected circulation) or, for example, clubbed fingers.

Links

Related articles

- Progressive changes
- Regeneration
- Reparation
- Atrophy
- Metaplasia
- Hyperplasia

External links



- Hypertrofie (czech wikipedia)
- Hypertrophy (english wikipedia)

Used literature

- MIŘEJOVSKÝ, Pavel – BEDNÁŘ, Blahoslav. *Obecná patologie*. 1. edition. Praha : Karolinum, 1994. 84 pp. ISBN 80-7066-950-0.
- MAČÁK, Jiří. *Obecná patologie*. 1. edition. Olomouc : Univerzita Palackého, Lékařská fakulta, 2002. 189 pp. ISBN 80-244-0436-2.