

Hodgkin Lymphoma

Hodgkin lymphoma, or **malignant lymphogranuloma**, is a cancer of the lymphatic tissue. The exact etiology is unknown (genetic predisposition, immune disorder, EBV, HIV). It is most often diagnosed between the ages of 20 and 30 and after the age of 50. The disease emerges in the Lymph node (most often in axial lymph nodes), from where it spreads to neighboring lymph nodes as well as to the systemic circulation.

Histologically, they are divided according to the number of **Reed-Sternberg cells** (cells formed by mutated B-cell) and according to the degree of cellular response.

- **type I** is also known as lymphocyte-rich HL with predominant lymphocytes (few RS cells with many lymphocytes; best prognosis) (5%);
- **type II** is also known as nodular sclerosing Hodgkin lymphoma (NSHL) (nodular foci with reticular cells, lymphocytes and histiocytes surrounded by collagens) (70%);
- **type III** is also known as mixed cellularity type (20-25%);
- **type IV** is also known as lymphocyte-depleted HL with small populations of lymphocytes (abundant proliferated RS cells; worst prognosis) (1%).

Clinical Manifestation

- Painless enlargement of the nodes (cervical, axillary, inguinal);
- Fever (pediatrics) (typically with Pel-Ebstein fever), itching, sweating, malaise, fatigue, weight loss;
- Splenomegaly;
- cough, dyspnea, superior vena cava syndrome (involvement of mediastinum);
- pleural/pericardial effusion, infiltration of parenchymal organs and/or bone marrow (in advanced stages).

Diagnostics

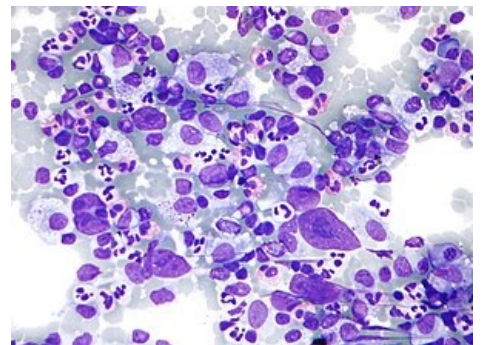
- Nodular extirpation and its subsequent histopathological examination - the presence of RS cells or Hodgkin's cell (RS cell precursors)
- Chest X-ray, abdominal ultrasound, scintigraphy of liver, spleen, CT and lymphography, PET;
- Trepanobiopsy of bone marrow.

Stages

- **Stage I** (involvement of single lymph node region or one extra-lymphatic organ);
- **Stage II** (involvement of 2 or more lymph node regions on a same side of diaphragm);
- **Stage III** (involvement of lymph node on both sides of the diaphragm, including extra-lymphatic organ or spleen);
- **Stage IV** (disseminated involvement of extra-lymphatic organs independent of nodal involvement).

Each stage is further divided into A and B:

- A - the patient is without systemic symptoms;
- B - the patient is with systemic symptoms (weight loss of 10% in 6 months, fever more than 38 ° C, night sweats).



Mikroskopický obraz Hodgkinova lymfomu

Complications

- Infections, spinal cord compression when the vertebrae are affected.

Therapy

The basic treatment method is systemic treatment by a combined chemotherapy, in localized stages radiotherapy is used to supplement. Basic regimens used are: **ABVD** (adriamycin, bleomycin, vinblastine, decarbazine), **BEACOPP** (bleomycin, stoposide, adriamycin, cyclophosphamide, vincristine, procarbazine, prednisone).

- **Localized** (early) stages I, II: 2 × ABVD and radiotherapy 20 Gy with favorable prognosis (without risk factors). 2×BEACOPP + 2×ABVD and radiotherapy 20 Gy with unfavorable prognosis (with risk factors)
- **Advanced** stages III, IV: 6×BEACOPP escalated mode
- In recurrent cases - **rescue regimen** (based on platinum derivatives), autologous transplantation.
- **New drugs** - brentuximab vedotin (anti-CD30 antibody) is used to treat recurrent HL. ^[1]

Prognosis

Patients have a good prognosis, about 70-80% of patients recover. The tumor is curable.

Links

Související články

- Malignant lymphoma
- non-Hodgkin malignant lymphoma
- Diffuse large B-cell lymphoma
- Leukemia
- Chemotherapy
- Radiotherapy

Reference

1. ČEŠKA, Richard, et al. *Interna*. 2. edition. Praha : Triton, 2015. 909 pp. ISBN 978-80-7387-895-5.

Bibliography

- ČEŠKA, Richard, et al. *Interna*. 2. edition. Praha : Triton, 2015. 909 pp. ISBN 978-80-7387-895-5.
- KLENER, Pavel, et al. *Vnitřní lékařství*. 4. edition. Praha : Galén, Karolinum, 2011. 1174 pp. ISBN 978-80-7262-705-9.

Classifications and references

- MKN-10 - C81 (<https://old.uzis.cz/cz/mkn/C81-C96.html#C81>)
- MeSH ID - D006689 (<https://www.medvik.cz/link/D006689>)
- MedlinePlus - 000580 (<https://medlineplus.gov/ency/article/000580.htm>)
- Medscape - 201886 (<https://emedicine.medscape.com/article/201886-overview>)