

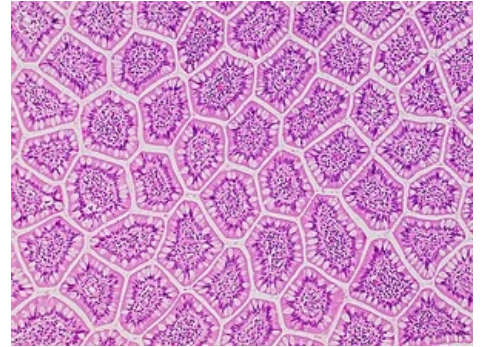
Histology MCQs/Gastrointestinal Tract

1 Are **von Ebner's glands** in the tongue associated with some structures?

- ☐ Yes, they are associated with lingual tonsil
- ☐ Yes, they are associated with vallate papillae
- ☐ Yes, they are associated with fungiform papillae
- ☐ No, they are not associated with other structures

2 **Circular folds** in the small intestine are based on projections of some layer of the wall. Which one?

- ☐ Nothing. These folds do not exist in the small intestine
- ☐ Muscularis externa
- ☐ Lamina propria
- ☐ Submucosa



Unusual view on the ileum

3 What are **crypts of Lieberkühn** (in the intestine) according to their structure and function?

- ☐ Ducts of glands in deeper layers
- ☐ Composed glands
- ☐ Alveolar glands
- ☐ Tubular glands

4 How is called the nerve plexus **in the submucosa** of the gastrointestinal tract?

- ☐ Solar plexus
- ☐ Meissner's plexus
- ☐ Auerbach's plexus
- ☐ There is no plexus in the submucosa

5 In which organ do we have eosinophilic **Paneth cells**?

- ☐ In the fundus of stomach
- ☐ In the pylorus of stomach
- ☐ In the small intestine
- ☐ In the large intestine

6 In which part of the digestive tube do we have main **Peyer's patches**?

- ☐ In the ileum
- ☐ In the jejunum
- ☐ In the colon ascendens
- ☐ In the colon descendens

7 **Tunica muscularis** of stomach has three layers. How are oriented fibers in the innermost layer (with respect to the longitudinal axis of stomach)?

- ☐ Muscle cells have longitudinal orientation
- ☐ Muscle cells have plexiform orientation
- ☐ Muscle cells have circular orientation
- ☐ Muscle cells have oblique orientation

8 Villi in the **large intestine** are finger-like projections of one layer of the wall. Which one?

- ☐ Lamina propria mucosae
- ☐ Tunica submucosa
- ☐ Tunica muscularis externa
- ☐ There are no villi in the large intestine

9 What are **taeniae coli**?

- ☐ Outer layer of tunica muscularis externa reduced on three strips composed of smooth muscle

- ☐ Outer layer of tunica muscularis externa reduced on three strips composed of striated muscle
- ☐ Inner layer of tunica muscularis externa reduced on three strips composed of smooth muscle
- ☐ Inner layer of tunica muscularis externa reduced on three strips composed of striated muscle

10 What is a **Brunner's gland**?

- ☐ Branched tubular mucinous gland sitting mainly in the submucosa of anus and rectum
- ☐ Branched tubular mucinous gland sitting mainly in the submucosa of duodenum
- ☐ Branched tubular mucinous gland sitting mainly in the submucosa of jejunum
- ☐ Branched tubular mucinous gland sitting mainly in the submucosa of ileum

11 What is a **lacteal**?

- ☐ Blood vessel in the lamina propria of the small intestine
- ☐ Blood vessel in the lamina propria of large intestine
- ☐ Lymphatic vessel in the lamina propria of the small intestine
- ☐ Lymphatic vessel in the lamina propria of large intestine

12 What is the function of **chief cells** in main gastric glands?

- ☐ Production of signaling molecules
- ☐ Production of digestive enzymes
- ☐ Production of hydrochloric acid
- ☐ Production of acid mucus

13 What is main function of **Paneth cells** in the intestine?

- ☐ Transportation of antigens through the epithelial barrier
- ☐ Production of antibacterial compounds
- ☐ Production of mucus
- ☐ Digestion of lipids

14 What is the function of **parietal cells** in main gastric glands?

- ☐ Production of hydrochloric acid
- ☐ Production of digestive enzymes
- ☐ Production of neutral mucus
- ☐ They are stem cells

15 What is an **intrinsic factor** which is produced in the stomach?

- ☐ Protein which protects vitamin B₁₂ against aggressive environment in the stomach
- ☐ Protein which protects vitamin C against aggressive environment in the stomach
- ☐ Lipid which protects vitamin B₁₂ against aggressive environment in the stomach
- ☐ Lipid which protects vitamin C against aggressive environment in the stomach

16 Where does have an adult man their **ameloblasts**?

- ☐ Ameloblasts are haphazardly distributed in the dental pulp
- ☐ Ameloblasts are in one layer between dentin and enamel
- ☐ Ameloblasts are in one layer between pulp and dentin
- ☐ An adult man has no ameloblasts

17 Which big salivary gland is **completely serous**?

- ☐ Apical lingual gland
- ☐ Submandibular gland
- ☐ Sublingual gland
- ☐ Parotid gland

18 Which big salivary gland is **mainly mucinous**?

- ☐ Apical lingual gland
- ☐ Submandibular gland
- ☐ Sublingual gland
- ☐ Parotid gland

19 What is main function of **Kupfer cells** in liver?

- ☐ They are stem cells for hepatic epithelial tissue
- ☐ They are stem cells for hepatic connective tissue
- ☐ They are tissue resident macrophages
- ☐ They are a storage of vitamin A

20 Which of following statements about **oesophageal glands** (*gl. oesophageales*) is true?

- ☐ They are small mucinous glands in the lamina propria
- ☐ They are small serous glands in the lamina propria
- ☐ They are small mucinous glands in the submucosa
- ☐ They are small serous glands in the submucosa

21 Which of following structures **does not take place** in the pancreas?

- ☐ Striated ducts
- ☐ Intercalated ducts
- ☐ Intralobular ducts
- ☐ Interlobular ducts

22 Which statement about **the outermost layer** of proximal (oral) part of the oesophagus is true?

- ☐ Proximal (oral) part of the oesophagus is not covered by serosa
- ☐ Proximal (oral) part of the oesophagus is covered by simple squamous epithelium called mesothelium
- ☐ Proximal (oral) part of the oesophagus is covered by stratified squamous epithelium called endothelium
- ☐ Proximal (oral) part of the oesophagus is covered by stratified squamous epithelium called mesothelium

23 Which statement about the lamina muscularis mucosae of pylorus is true?

- ☐ Lamina muscularis mucosae does not exist in the pylorus
- ☐ Lamina muscularis mucosae is composed of smooth muscle cells
- ☐ Lamina muscularis mucosae is composed of striated muscle fibers
- ☐ Lamina muscularis mucosae is composed of both smooth muscle cells and striated muscle fibers

24 Which structure takes place in the middle of **the liver acinus** (Rappaport's acinus)?

- ☐ Bile duct
- ☐ Central vein
- ☐ Hepatic artery
- ☐ There is no obvious structure in the middle of the liver acinus

25 Which structures form borders of **Disse's space** (space of Disse)?

- ☐ Two hepatocytes
- ☐ Ito's cells and a wall of sinusoid
- ☐ Hepatocytes and a wall of sinusoid
- ☐ Kupfer's cells and a wall of sinusoid

Submit

Links

- List of all tests: Histology MCQs
- Portal:Histology