

# Histiocytosis

A **histiocytosis** is a heterogeneous group of diseases characterized by tumorous proliferation of histiocytes. Histiocytes are macrophages, that can be found in the lymph node stroma, they are part of the reticuloendothelial (or monocyte-macrophage) system. They are formed by the entry of monocytes (mononuclear cells) into tissues.

These diseases are sometimes classified as lymphomas. When their precursors proliferate in the bone marrow, **monocytic leukemia** develops. When immature histiocytes proliferate in tissues, **histiocytic medullary reticulosis** develops. The proliferation of mature histiocytes is collectively called **Langerhans cell histiocytosis** (formerly histiocytosis X)<sup>[1]</sup>. *Langerhans cell histiocytoses* (dendritic cells) and *hemophagocytic lymphohistiocytoses* (macrophages) are typical for childhood.

## Classification

### Classification of histiocytic diseases, according to WHO classification of blood diseases (2001)

- Histiocytic sarcoma,
- Langerhans cell histiocytosis (LCH),
- Langerhans cell sarcoma,
- interdigitating dendritic cell tumor,
- follicular dendritic cell sarcoma.<sup>[2]</sup>

### Classification of histiocytic diseases according to the International Histiocyte Society

- I. class - Langerhans cell histiocytosis,
- II. class - hemophagocytic lymphohistiocytosis:
  - familial erythrophagocytic lymphohistiocytosis (FHLH),
  - hemophagocytic lymphohistiocytosis,
  - infection-associated haemophagocytic syndrome,
- III. class - malignant histiocytosis:
  - acute monocytic leukemia,
  - true histiocytic lymphoma.<sup>[2]</sup>

## Langerhans cell histiocytosis (LCH, histiocytosis X)

This is a monoclonal proliferation of Langerhans cells - special skin dendritic cells. It most often occurs between the 1st and 3rd years of life. It is not a malignant disease in the classical sense (here we can find morphologically mature cells, spontaneous regression, and no aneuploidy).<sup>[3]</sup>

### Epidemiology and etiopathogenesis

The incidence is 0.4: 100,000 children under 15 years of age. Boys are affected twice as often as girls.<sup>[3]</sup> The origin is unclear - viral origin, primary immune defect, or malignancy is considered. Normal Langerhans cells do not divide further, while cell proliferation occurs in Langerhans cell histiocytosis. These cells further migrate to other organs.

### Histopathology

An infiltrate of pathological Langerhans cells, macrophages, lymphocytes, eosinophilic granulocytes, and giant osteoclast-like cells is typically present in lesions. All of these cells produce cytokines that cause fibrosis and tissue necrosis and bone resorption.<sup>[4]</sup> The presence of Birbeck granules (tennis-rock-shaped intracellular particles) or CD1a antigen on the cell surface can be detected with an electron microscope.<sup>[3]</sup>

### Clinical manifestation

- manifestations at any age,
- The most common manifestations - osteolytic bone lesions (skull, long bones, pelvis, ribs, spine) - eosinophilic bone granuloma - and painful swelling of the soft tissues,
- skin disorders - seborrheic, scaly, or xanthomatous papules,
- hepatopathy with hepatomegaly → jaundice, hypoproteinemia, edema, ascites,
- hematopoietic dysfunction → anemia, leukocytopenia, thrombocytopenia,
- lung involvement → cough, dyspnoea,
- brain involvement → diabetes insipidus.<sup>[3][2]</sup>

### Clinical forms

- Letterer-Siwe disease (typically up to 2 years of age): disseminated multisystem form; fever, skin rash, bone

lesions, bone marrow involvement (cytopenia), lymphadenopathy, hepatosplenomegaly, jaundice, interstitial lung changes with dyspnoea and pneumothorax.<sup>[4]</sup>

- Hand-Schüller-Christian disease (typical for ages 2-6): polyuria, exophthalmos, lytic defects of flat bones.
- Eosinophilic bone granuloma (adult age).<sup>[2]</sup>

## Staging

1. Localized disability (predominant in adulthood):
  - bones - monostotic / polyostotic, skin, lungs, lymph nodes, CNS,
2. disseminated disability (predominant in childhood):
  - affected 2 or more organs with / without organ dysfunction.

## Diagnostics

- Histological evidence - with a microscope,
- immunohistological detection of CD1a antigen on the cell surface,
- electron microscopic detection of Birbeck granules in the cytoplasm of a cell lesion. <sup>[3]</sup>

## Histological development LCH deposits over time

1. Proliferative stage (predominantly Langerhans cells),
2. granulomatous stage (varied cytology),
3. xanthomatous stage, and scarring. <sup>[2]</sup>

## Treatment

- excochleation in case of isolated bone infection,
- steroids and vinblastine in case of multiple bones infection,
- combined cytostatic treatment in case of multi-organ involvement. <sup>[3]</sup>

## Prognosis

- If one organ is affected, the probability of survival is 100%,
- in multiorgan impairment, the lethality is 20%. <sup>[3]</sup>

## Hemophagocytic lymphohistiocytosis

These are reactive, often fatal histiocytoses, typically occurring in infants. Based on the immune defect, there is an ineffective immune response with the activation of lymphocytes, macrophages, and hemophagocytosis. This immunodeficiency can be genetically determined (familial hemophagocytic lymphohistiocytosis) or secondarily acquired immunodeficiency. <sup>[3]</sup>

Lymphohistiocytosis may occur in young patients with Crohn's disease who are treated with azathioprine. Tissue destruction is caused by a viral infection (most often EB virus), which triggers excessive activation of the immune system. The disease then resembles infectious mononucleosis - there are fever, splenomegaly, and liver lesions. Pancytopenia is noticeable in the blood count. Most patients die of multiorgan failure.<sup>[5]</sup>

## Familial hemophagocytic lymphohistiocytosis (FHLH)

- Synonym: Farquhar disease (*Morbus Farquhar*).

## Epidemiology and etiopatogenesis

The incidence is 1: 50,000. <sup>[3]</sup> Boys and girls are affected equally. At least 3 different gene defects cause an ineffective immune response with large leaching of inflammatory cytokines and uncontrolled activation of histiocytes.

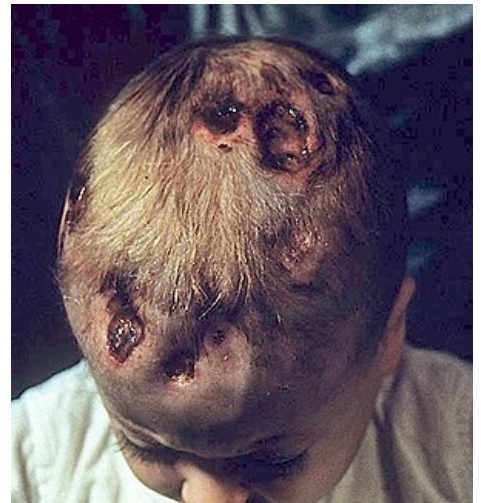## Histopathology

Diffuse lymphocyte infiltration of the liver, spleen, lymph nodes, bone marrow, and brain is characteristic.

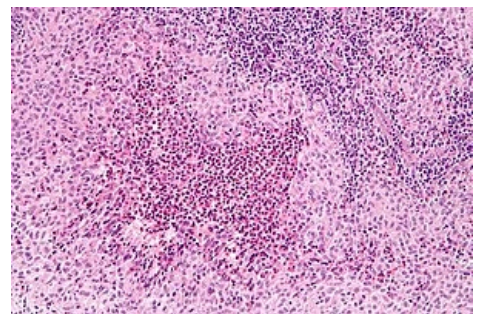
Histiocytes are benign and actively phagocytose erythrocytes ("hemophagocytes"), nuclear cells, and platelets. <sup>[3]</sup>

## Clinical manifestation

- Fever, hepatosplenomegaly, and pancytopenia,
- swelling of the local nodes, swelling, icterus, exanthema,
- neurological symptoms - bouts of convulsions and paralysis of cranial nerves,



A child with a lytic defect of skull bones, Hand-Schüller-Christian disease



Langerhans cell histiocytosis

- progressive neutropenia → severe bacterial or fungal infections up to death <sup>[3]</sup>

## Diagnostics

- Pancytopenia,
- hypertriglyceridemia, increased aminotransferase activity in serum, decreased fibrinogen, increased ferritin, only mild CRP elevation,
- decreased activity of NK cells, pro- and anti-inflammatory cytokines in plasma,
- bone marrow: lymphohistiocytic infiltration, haemophagocytosis,
- cerebrospinal fluid: mild pleocytosis, increased protein,
- MRI of the brain: brain atrophy and foci of demyelination. <sup>[3]</sup>

## Treatment

- Steroids and etoposide, event. cyclosporin A and anti-thymocyte globulin (ATG),
- in case of brain involvement, intrathecal treatment with methotrexate,
- complete cure is only possible by bone marrow transplantation. <sup>[3]</sup>

## Prognosis

- The untreated disease is fatal,
- in bone marrow transplantation, the chance of cure is 50-70%. <sup>[3]</sup>

## History

The term "histiocytosis X" was first used by Lichtenstein in 1953. The name arose due to the unclear etiology and embarrassment of whether the disease was classified as a tumor or infectious disease, or a lipid thesaurus. The original name histiocytosis X was later changed to the term Langerhans cell histiocytosis (LCH). This disease is classified by the WHO classification of blood diseases into the group of malignant histiocytic diseases. <sup>[2]</sup>

## References

### Related articles

- Macrophages
- Immunocompetent cells
- Granulomatous lung processes

### Reference

Wikiskripta (<https://www.wikiskripta.eu/w/Histiocyt%C3%B3zy%7CWikiskripta%7C>)

1. KLENER, Pavel. *Vnitřní lékařství*. 3. edition. 2006. ISBN 80-7262-430-X.
2. ADAM, Z. – VANÍČEK, J. – ŠLAMPÁ, P. Histiocytóza z Langerhansových buněk u osob dospělého věku. *Vnitřní lékařství* [online]. 2006, vol. 52, p. 355-370, Available from <[http://www.vnitrnilekarstvi.eu/pdf/vl\\_06\\_05\\_11.pdf](http://www.vnitrnilekarstvi.eu/pdf/vl_06_05_11.pdf)>. ISSN 1801-7592.
3. MUNTAU, Ania Carolina. *Pediatric*. 4. edition. 2009. ISBN 978-80-247-2525-3.
4. LEBL, J – JANDA, J – POHUNEK, P. *Klinická pediatrie*. 1. edition. 2012. ISBN 978-80-7262-772-1.
5. ROZSYPAL, Hanuš. *Základy infekčního lékařství*. 1. edition. 2015. ISBN 978-80-246-2932-2.