

# Gastrinoma

**Gastrinoma** is a tumor with increased gastrin production, most often located in the pancreas. It is based on the G-cells of the pancreatic islets of Langerhans. Gastrinoma grows slowly but may be locally invasive; but more often it metastasizes. Due to increased gastrin production, high secretion of gastric juice with a high content of HCl and proteinases occurs, which leads to the repeated formation of peptic ulcers, especially in the duodenum, but they can also occur in the stomach, esophagus or jejunum. In 50% of cases, the patient develops diarrhea. The disease caused by excess of gastrin is called **Zollinger-Ellison syndrome**.

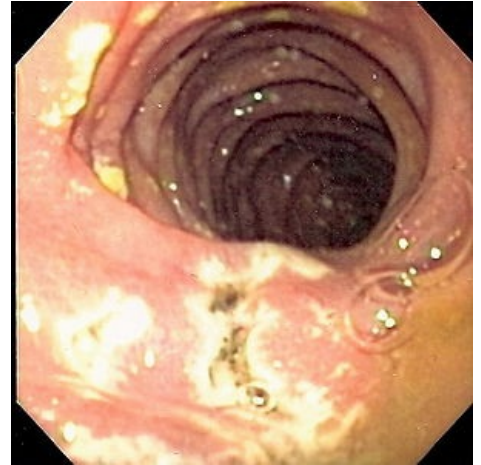
## Links

### Related articles

- Pancreatic tumors
- Zollinger-Ellison syndrome

### References

- 
- POVÝŠIL, Ctibor a Ivo ŠTEINER. *Special pathology*. 2. edition. Prague : Galén : Karolinum, 2007. ISBN 978-80-246-1442-7.



Endoscopic picture of multiple peptic ulcers in the distal duodenum in a patient with Zollinger-Ellison syndrome based on gastrinoma.