Ganglion oticum + ganglion submandibulare

Otic ganglion

- One of the four parasympathetic ganglia of the head and neck
- Lies in the infratemporal fossa, in close relation with foramen ovale
- Types of fibers involved with otic ganglion:

1. Parasympathetic
2. Sympathetic
3. Somatomotor

- Only the parasympathetic fibers synapse in this ganglion
- The rest of the fibers only pass through it
- Sympathetic fibers come from external carotid artery (->middle meningeal artery)
- Parasympathetic fibers are transmitted through lesser petrosal nerve. Those parasympathetic fibers are responsible for the innervation of parotid gland (via auriculotemporal nerve)
- Also through otic ganglion, without synapsing, pass the somatomotor fibers which are responsible for the innervation of tensor veli palatini and tensor tympani muscles (derived from motor part of mandibular division of trigeminal nerve)

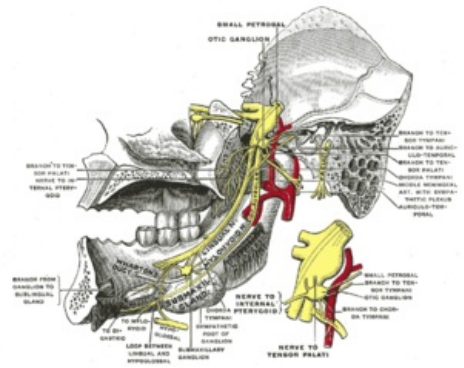

otic ganglion

Submandibular ganglion

- Also one of the four parasympathetic ganglia of the head and neck
- Is seen like "hanging" from lingual nerve (posterior V3) by two small fibers; one anterior and one posterior
- Types of fibers involved with submandibular ganglion:

1. Parasympathetic
2. Sympathetic

- Sympathetic fibers (postganglionic) come from the external carotid artery and pass through the ganglion without synapsing
- Preganglionic parasympathetic fibers synapse in this ganglion
- Preganglionic parasympathetic fibers pass via chorda tympani nerve to lingual nerve and end in the submandibular ganglion
- Postganglionic parasympathetic fibers are responsible for the innervation of submadibular and sublingual glands

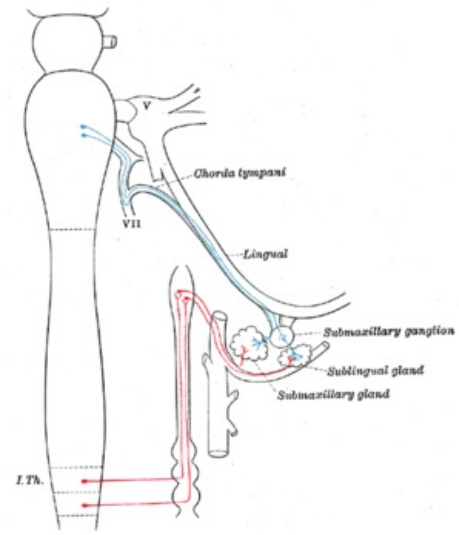

Submandibular ganglion