

# Furuncle

Abscessing purulent inflammation of the hair follicle or skin glands, causing necrosis of the epithelium and spreading to the surrounding area. Pus with necrotic tissue remnants bursts through the thinned epidermal layer to the outside.

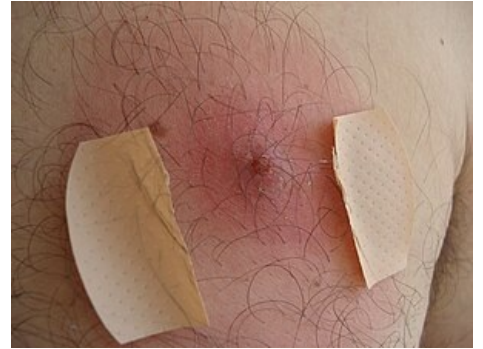
## Links

### Related articles

- Carbuncle
- Impetigo
- Panaritium
- Pyodermia

### Source

- POVÝŠIL, Ctibor – ŠTEINER, Ivo. *Obečná patologie*. 1. edition. Galén, c2011. ISBN 978-80-7262-773-8.



Furuncle