

Falx inguinalis

Falx inguinalis (also *tendo conjunctivus*) is a structure that is formed by the fusion of the lower edges of the aponeuroses of the obliquus internus abdominis and transversus abdominis muscles. It borders the trigonum inguinale medially.

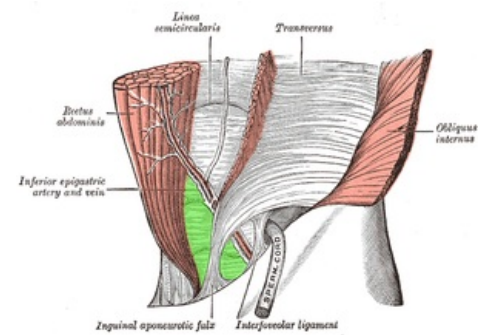
Links

Related articles

- Trigonum inguinale
- Obliquus internus abdominis muscle
- Abdominal muscles (table)

References

- ČIHÁK, Radomír. *Anatomie 1*. 2. edition. Praha : Grada, 2001. 497 pp. ISBN 80-7169-970-5.
- KACHLÍK, David. *Katalog LF3 – Svaly* [online]. [cit. 2015-11-12]. <<http://katalog.lf3.cuni.cz/svaly/kategorie/346/?sestava>>.



Trigonum inguinale (green), falx inguinalis medially