

External Carotid Artery

NETTER, Frank. *Atlas of Human Anatomy*. 4th edition. 2006. ISBN 13 978-1-4160-3385-1.

Branches of External Carotid Artery

- External carotid artery has 8 branches
- The branches are the following:

1. Ascending pharyngeal
2. Superior thyroid
3. Lingual
4. Occipital
5. Facial
6. Maxillary
7. Posterior auricular
8. Superficial temporal

Medial Branches

- Ascending pharyngeal

Posterior Branches

1. Occipital
2. Posterior auricular

Anterior Branches

1. Superior thyroid
2. Lingual
 1. Dorsal lingual
 2. Sublingual
 3. Deep lingual
3. Facial
 1. Submental
 2. Inferior labial
 3. Superior labial
 4. Angular
4. Maxillary

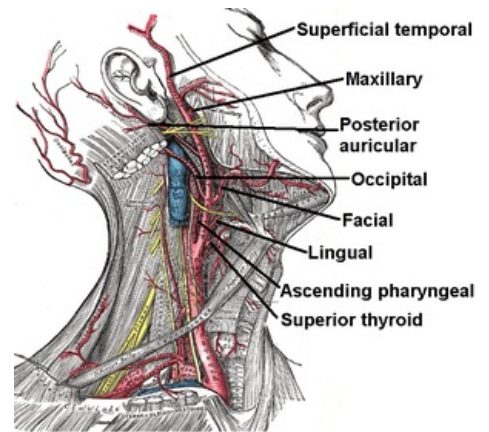
Terminal Branch

- Superficial temporal
1. Transverse facial
 2. Zygomatico-orbital
 3. Parietal branch (of superficial temporal)
 4. Frontal branch (of superficial temporal)

Links

Related Articles

- Carotid Triangle



External carotid artery