

# Esophagus

This article has been translated from WikiSkripta; ready for the **editor's review**'.

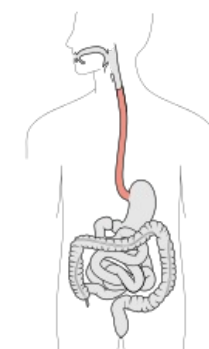
**The Esophagus is a 23-28 cm** long tubular organ connecting the pharynx and the stomach. It connects to the pharynx at the level of the C6 vertebra, then descends through the chest in front of the spine and ends at the level of the Th 11 vertebra by opening into the stomach - in the *ostium cardiacum*. At rest, the esophagus has a diameter of about **1.5 cm** and is flattened anteroposteriorly. When taking in food, it is able to expand to twice its normal diameter. In its wall, we find muscle, which in the aboral direction changes from skeletal (the upper third of the esophagus) to smooth. It is lined with mucous membrane.

Its main function is the active movement of food and liquids from the mouth to the stomach. Muscle enables this active movement peristalsis.

## Anatomical structure of esophagus

The esophagus is slightly bent. At its beginning, it is located in the midline, on the neck and in the upper part of the chest it arches to the left, in the middle part of the chest it passes to the right side, above the diaphragm it bends again to the left side and goes down to the *ostium cardiacum*. The esophagus is divided into three parts:

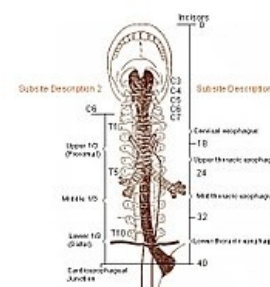
1. **Pars cervicalis** - in this part, the trachea descends in front of the esophagus (this is why the esophagus is shifted slightly to the left);
2. **pars thoracica** - the longest section of the oesophagus, the *trachea* divides in front of it into two *bronchi*;
3. **pars abdominalis** - the shortest section (1-2 cm long), from the *hiatus oesophageus* of the diaphragm to the *ostium cardiacum* of the stomach.



Esophagus

There are natural "narrowings" on the esophagus, the distance of which is calculated from the incisors and are important for orientation during endoscopy:

1. Between the scrotum and the spine - 15 cm from the incisors;
2. at the point where the aorta attaches from the left - it is not constant, 22.5 cm from the incisors,
3. at the crossing point with the left bronchus (between it and the descending aorta) - 27.5 cm from the incisors.
4. in the hiatus oesophageus of the diaphragm - 40 cm from the incisors.



## Histological structure of esophagus

Error: Image is invalid or non-existent.

The esophagus is a muscular tube connecting the pharynx and the stomach. It consists of 4 layers typical of the general structure of the alimentary canal:

- tunica mucosa (mucosa);
- tela submucosa (submucosa);
- tunica muscularis externa (external muscle);
- adventitia + serosa.

### Tunica mucosa

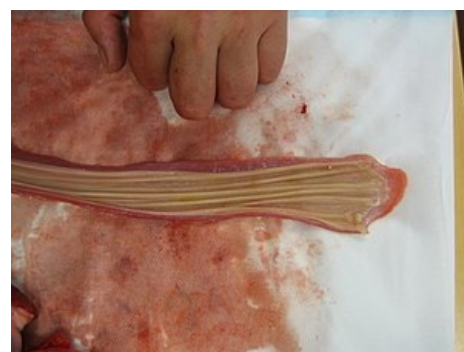Consists of :

- superficial epithelium (multilayered squamous without cornification);
- lamina propria mucosae (sparse collagenous tissue, near the stomach with cardiac glands);
- lamina muscularis mucosae - smooth muscle;
- poorly graspable glands.

### Tela submucosa

The tela submucosa contains fibroelastic tissue. Here we find groups of small mucinous glands (glandulae oesophagicae) and the autonomous nerve plexus of Meissneri.

### Tunica muscularis externa



Esophagus

It contains two layers of muscle - inner circular and outer longitudinal. The upper third of the esophagus is made up of ``striated *skeletal muscle*, the middle third is made up of ``mixed muscle, and the lower third is made up of ``smooth *muscle*. Between the inner and outer layers of muscle is the *Auerbach* autonomic nerve plexus.

## Serosis and adventitia

The serosa covers only the part of the esophagus below the diaphragm that extends into the abdominal cavity. Adventitia is a thin tissue that covers the cervical and thoracic section of the esophagus and smoothly transitions from it into the surrounding tissue and into the tissue of the mediastinum.

## Preparation

Esophagus preparation is often confused with vagina preparation. However, unlike the vagina, the esophagus has a darker epithelium, contains glands, more fibroelastic tissue and well-distinguishable layers of muscle (muscularis externa).

## Links

### Related Articles

- Esophageal injuries
- Esophagus/histology
- Digestive system

'*Practicing histological preparations*

- Practice:Digestive System

### External links

- Esophagus(Czech Wikipedia)
- Esophagus (English Wikipedia)

### References

- WIKIPEDIA SK. *Esophagus* [online]. ©2005. The last revision 2010-05-11, [cit. 2010-04-20]. <<http://sk.wikipedia.org/wiki/Pa%C5%BEer%C3%A1k>>.
- JUNQUIERA, L.Carlos – CARNEIRO, Jose – KELLEY, Robert O, et al. *Fundamentals of Histology*. 1. edition. Jinocany : H & H, 1997. 502 pp. ISBN 80-85787-37-7.
- ČEDÍKOVÁ, Miroslava. *GIT II* [lecture for subject histology and embryology, specialization general medicine, LFP UK]. Pilsen. ?.
- LÜLLMANN-RAUCH, Renate. *Histology*. 2. edition. Grada Publishing a.s., 2012. 556 pp. ISBN 9788024737294.