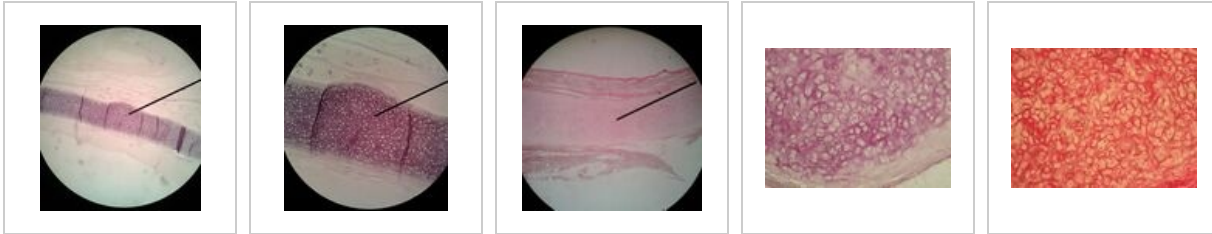


# Epiglottis (slide)

## Overview of the slides



## Connective tissue

- Mesenchyme (slide)
- Pupečník (slide)
- Aorta (slide)
- Brown adipose tissue (slide)
- White adipose tissue (slide)
- Tendon (slide)
- Articular cartilage (slide)
- Epiglottis (slide)
- Desmogeic ossification (slide)
- Endochondral ossification (slide)
- Lamelous bone (slide)

## Links

### Further images

- Epiglottis (histological slide)

### Related articles

- Epiglottis
- Atlas of histological slides/Respiratory tract
- Cell basis of medicine (3. LF UK)
- Epiglottis (Wikipedia) (<https://www.wikiskripta.eu/index.php?curid=34402>)
-