

Endocrine diseases of the gonads

Primary testicular disorders

Clinical manifestations of testicular disorders and their examination

- Manifestation in prepubertal deficits androgens: lack of development of secondary sexual characteristics, development of eunuchoid skeletal proportions, penis and testes remain small, typical scrotal wrinkling does not remain, higher position remains voice, full muscle development, potency disorder and infertility.
- Manifestation in postpubertal androgen deficiencies: decreased libido, potency and infertility, slows beard growth, development of osteopenia and osteoporosis.

Laboratory examination: basic determination of hormones – testosterone, FSH, LH, prolactin, estradiol, free testosterone, dihydrotestosterone, SHBG, hCG. **Dynamic tests :**

- Stimulation test with hCG - given 3 days in a row after 3000 .mu.m. → stimulation of steroid synthesis and secretion by Leydig cells → normal response to plasma testosterone is normal.
- GnRH Assay - 0.1 mg of GnRH is administered i.v. → 2-5 × increase in LH and twofold increase in FSH.

Bilateral anorchy

- occurs in about 1 in 20,000 men,
- **testicular death during fetal development,**
- ↓ level testosterone u, ↑ gonadotropin.

Therapy:

- long-term androgen substitution,
- implantation of testicular prostheses.

Cryptorchidism

- **testicular dystopia** (retention of testicles at the descent path, 77%)
- **ectopia** (off the path of normal descent, 23 %);

Complications:

- torsion,
- trauma,
- development of a malignant testicular tumor (about 20-30 times higher incidence than in healthy men) - untreated can cause infertility;

Therapy – as soon as possible:

- hormonal - intramuscular human chorionic gonadotropin (hCG), or intranasal treatment with gonadotropin hormone (GnRH),
- surgical - recommended between 12-18. month old.

Klinefelter's syndrome (47,XXY)

🔍 For more information see Klinefelter's Syndrome.

- the most common cause of male hypogonadism,
- classic karyotype is 47, XXY, but there are other variants 48, XXXY, 49, XXXXY, 48, XXYY, or mosaic 47, XXY / 46, XY;

symptoms:

- manifestations usually during puberty,
- eunuchoid habitus,
- development gynecomastia in puberty,
- small testes with azoospermia, infertility, decreased libido,
- rare pubic and axillary hair,
- long-term → development osteopenia,
- 20 times higher incidence of breast cancer compared to healthy men;

Therapy:

- substitution androgens: most recently - transdermal patches,
- infertility treatment under assisted reproduction methods.



Anorchia

Seed canal failure in adulthood

etiology:

- inflammation as mumps complications, gonococcal, irradiation, uremia, alcoholism, narcotics, paraplegia, lead poisoning, chemotherapy, varicocele;
- idiopathic

symptoms:

- infertility,
- with more severe androgen-deficient testicular atrophy;

diagnosis:

- oligospermia to azoospermia,
- hormones usually in the norm,

therapy:

- elimination of the cause,
- in hypogonadism, androgen replacement therapy.

Decrease in Leydig cell function in adulthood and old age - climacterium virile

- gradual **decrease in gonadal function** during aging → decrease in libido, potency, emotional lability.

Central (hypothalamic-pituitary) causes of testicular dysfunction

Hypogonadotropic hypogonadism

- is caused by a disorder of gonadotropin secretion both at the level of the pituitary gland and in the hypothalamus or higher centers of the brain,
- **isolated deficit** luteinizing hormone **LH** (Pasqualini syndrome, fertile eunuchoidism) – affected by LH and testosterone secretion,
- part of a disorder of secretion of multiple pituitary hormones,

Symptoms: it depends on whether it develops pre- or postpubertally, **Diagnosis:**

- ↓ LH, ↓ FSH (follicle-stimulating hormone),
- when GnRH is stimulated in a hypothalamic lesion, ↑ & nbsp; LH and FSH occur (unlike the pituitary lesion),

Therapy:

- application of FSH, LH,
- application in hypothalamic disorders of GnRH.

Hyperprolactinemia

- is the cause of infertility in about 4% of infertile men,

Symptoms:

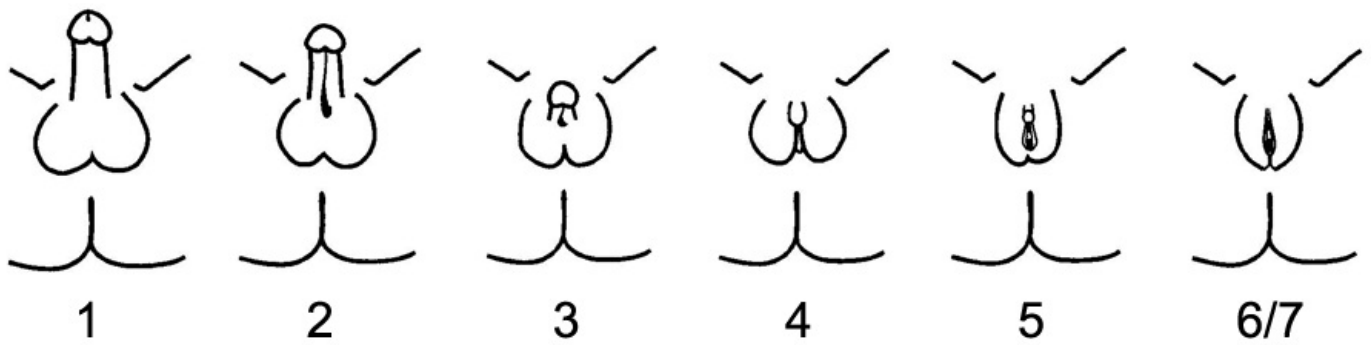
- loss of libido and potency,
- decreased ejaculate volume, oligospermia,
- rarely gynecomastia, galactorrhoea,

Diagnosis:

- ↑ prolactin, ↓ testosterone,
- LH and FSH reduced or below standard

therapy:

- dopamine ergon agonists,
- optionally substitution with androgens or gonadotropins (to achieve fertility).



Disorders of the action of androgens

- may be at any stage of action of androgens on target tissues → lead to male pseudohermaphroditism.

Androgen insensitivity syndrome (testicular feminization syndrome)

- level disorder **androgen receptor**,

Symptoms:

- karyotype **46,XY**, female phenotype,
- blind-ended vagina,
- ectopic testicles,
- primary amenorrhea,
- axillary or pubic hair is rare or absent.

Incomplete forms of androgen insensitivity

- patients with **testicular feminization** to **normal men** with signs of hypogonadism and spermiogenesis disorders.

Gynecomastia

Gynecomastia is an enlargement of the mammary gland **in men**. We distinguish:

1. True gynecomastia - mammary gland proliferation;
2. Pseudogynaecomastia - increased fat storage in the breast area;

the cause is an absolute or relative **increase in estrogen concentration**.

Physiological

- in newborns;
- in puberty;
- in men on the transition to hay.

Pathologically:

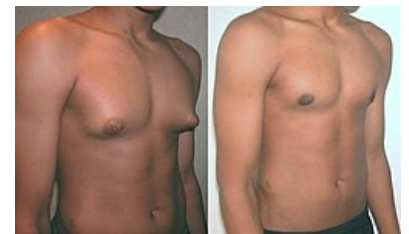s*ome estrogen-producing testicular or kidney tumors;

- cirrhosis;
- thyrotoxicosis;
- drugs (spironolactone, cimetidine, psychotropic drugs);
- Gynecomastia occurs in 56-88% of cases of Klinefelter's syndrome. [1]

Therapy:

- elimination of the root cause;
- in pubertal gynecomastia - androgens, antiestrogens (Tamoxifen State Office for Drug Control: Tamoxifen); [2]
- surgical therapy.

The course of surgical removal



Gynecomastia

Gynecomastia in men can also be removed surgically by performing a plastic operation, where an incision is made around the areola. This operation takes place under general anesthesia. [3]

Primary ovarian disorders

- *manifestations of endocrine disorders of the ovaries*

1. manifestation of premature and delayed estrogen secretion,
2. estrogen deficiency → leads to osteoporosis, accelerated atherosclerosis, lower urogenital tract atrophy with infections and dysfunction, skin atrophy, alopecia and hirsutism, psychological changes, vasomotor climacteric symptoms - hot flushes, sweating, flushing,
3. menstrual disorders in adult women and infertility,
4. excessive androgen secretion → development of hirsutism, acne, alopecia, cycle disorders.

Turner syndrome

- **karyotype 45,X**, structural chromosomal aberrations of the X chromosome or chromosomal mosaic with line 45, X are also possible

Symptoms:

- absence of puberty, small stature (average final height is 143 cm),
- skin rash on the neck - pterygium coli,
- micrognathia,
- lymphedema of the hands and feet after birth,
- abnormalities kidneys,
- aortic coarctation,
- arterial hypertension,
- pigmented nevi,

biochemistry:

- ↓ estradiol, ↑ gonadotropins,

Therapy:

- affecting the final height (growth hormone),
- hormone replacement (estrogens + progestogens).

Premature ovarian failure

- *'ovarian loss in women of childbearing age'*,

etiology:

- antibodies against ovaries - possibly autoimmune etiology,

therapy:

- estrogen + progestogen substitution.

Central ovarian disorders

Hypogonadotropic hypogonadism

- in the case of an isolated disorder before puberty, puberty does not develop - symptoms:

have ↓ gonadotropins and estradiol,
normal height,

- adult disorder - symptoms:

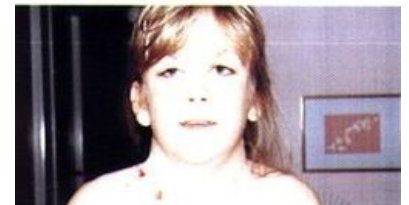secondary oligomenorrhea to amenorrhea,

therapy:

- *substitution by estrogens and progestogens:*

there must be a combination - estrogens alone increase the incidence of endometrial cancer (only in women after hysterectomy estrogens alone),
* cyclic application

either we administer estrogens continuously and for half an month we add additional progestogens; or we administer estrogens for 3 weeks → we skip 1 week → then we add progestogens for 10-12 days in the second half of the cycle,
treatment interruption → cyclic uterine bleeding,



Pterygium coli in Turner syndrome

* continuous application

permanent administration of estrogens and progestogens,
continuous administration of the progestogen gradually leads to atrophy of the endometrium, the woman stops bleeding after a certain time,

- *substitution of gonadotropins FSH and LH:*

applied to achieve follicle maturation, ovulation and pregnancy in central forms of hypogonadism,

- *GnRH substitution:*

ovulation and pregnancy can also be achieved in this way.

Hyperprolactinemia

1. 'mild hypersecretion' - causes anovulation,
2. 'higher hypersecretion' - oligomenorrhea to amenorrhea; may be accompanied by a galactorium,

therapy:

- depends on etiology,
- dopaminergic agonists.

Ovarian dysfunction associated with androgen hypersecretion

Polycystic ovary syndrome (Stein-Leventhal syndrome)

symptoms:

- infertility, hirsutism and acne, anovulatory cycles, or oligomenorrhea to amenorrhea,
- obesity, insulin resistance, ↑ occurrence DM,
- hypertension,

diagnosis:

- ↑ LH, ↑ serum androgens or their metabolites in urine,
- enlarged, glossy, white, polycystic ovaries with thickened tunica albuginea,

therapy:

- to control ovulation: clomiphene citrate,
- treatment of hirsutism and acne.

Hirsutism

symptoms:

- **increased growth** pigment of hairs **in women** in places where male hair is typically present (face, upper lip, chin, neck, chest, back, inner thighs),
- acne, oily skin,
- oligomenorrhea to amenorrhea,
- **virilization** - somatic changes: hair corners, coarser voice, breast atrophy, enlarged clitoris, male muscle formation,

causes of hirsutism:

- increased androgen production in ovaries or adrenals,

therapy:

- antiandrogens - block the effect of androgens on receptors (cyproterone acetate),
- contraceptives.

Links

Reference

1. VISOOTSÁK, Jeannie a John M GRAHAM. Klinefelter syndrome and other sex chromosomal aneuploidies. *Orphanet J Rare Dis* [online]. 2006, vol. 1, s. 42, dostupné také z <<https://orjrd.biomedcentral.com/articles/10.1186/1750-1172-1-42>>. ISSN 1750-1172.
2. ↑ Zvětšení prsou u mužů je běžné. *Idnes* [online]. Praha, 2007 [cit. 2021-10-27]. Dostupné z: https://www.idnes.cz/onadnes/zdravi/zvetseni-prsou-u-muzu-je-bezne.A070920_095937_zdravi_bad

3. ↑ Gynekomastie. *Medicom Clinic* [online]. [cit. 2021-10-27]. Dostupné z: <https://www.medicomclinic.cz/gynekomastie>

Used literature

- MAREK, Joseph – BRODANOVÁ, Mary. *Internal Medicine Volume VI.*. second edition. Galen publishing house, 2002. 266 pp. pp. 102 - 111. ISBN 80-7262-169-6.
- KÁBRT, Jan. – KÁBRT, Jan.. *Lexicon of Medicine*. 2. edition. Galen, 1995. pp. 791. ISBN 80-85824-10-8.