



Emphysema

Emphysema:



Emphysema 2:



Emphysema is, in a broader sense, the accumulation of air in the tissues. In the awareness not only of the lay public, but also of the professional public, the term emphysema mainly means **pulmonary emphysema**. However, we also encounter accumulation of air in other structures, e.g. in **the mediastinum** or in **the subcutaneous tissue**. In the mentioned locations, we use the term mediastinal, or subcutaneous emphysema.

Types of emphysema

1. **Subcutaneous;**
2. **mediastinal;**
3. **pulmonary emphysema.**

Clinical picture of subcutaneous and mediastinal emphysema

When **the air in the subcutaneous tissue** (especially on the chest) **increases**, we feel a cracking under the fingers caused by the movement of air in the interstitium. Subcutaneous emphysema is often an accompanying symptom of various serious diseases, such as pneumothorax, broken ribs, penetrating traumatic injuries, and also occurs in gas phlegmon.

In case of **mediastinal emphysema** (pneumomediastinum), there is a very typical noisy friction murmur on auscultation over the mediastinum, which is synchronous with heart activity (the so-called Hamman's sign). The possibility of pneumomediastinum should be considered especially *if subcutaneous emphysema occurs at the same time*. However, we cannot ignore the fact that both **crepitation** (a symptom of subcutaneous emphysema) and a pleural friction murmur can imitate sounds caused by chest hairs rubbing against the attached stethoscope. An experienced physician can prevent these sounds by moistening the skin of the chest before the examination.

Diagnosis of pulmonary emphysema

The diagnosis of pulmonary emphysema is a pathological-anatomical diagnosis. It is sometimes very difficult for the clinic (especially in the beginning forms) to detect pulmonary emphysema, therefore, especially in European countries, the name **obstructive bronchopulmonary disease** was used more for these conditions (before the creation of this name, Europe talked about chronic bronchitis, while in America they talked about pulmonary emphysema, although it was a clinically identical condition).

Originally, pulmonary emphysema meant an increase in the volume of air in the lungs. Currently, the pathological-anatomical definition cited above is recognized. – **Emphysema is dilatation of the airways distal to the respiratory bronchiole** (i.e. at the level of acini and alveoli) **and destruction of interalveolar septa**.

Hyperinflation during an attack of bronchial asthma was previously referred to as acute emphysema, while the name compensatory emphysema was used for pneumonia, atelectasis or lobectomy. The diagnosis of senile emphysema was replaced by the much more accurate name of senile pulmonary atrophy.

Types of pulmonary emphysema

The current division of emphysema is based on the recommendations of experts of the English commission - the essence of this division is the pathological-anatomical finding.

1. **Emphysema with non-selective distribution** – affecting the entire acinus , without selection, i.e. non-selectively. In this case, the name **panacinar destruction emphysema** is often used.
2. **Emphysema with selective distribution**, which selectively affects primarily the proximal part of the acinus during obstruction of the respiratory bronchiole. This type of emphysema is referred to as **centrilobular emphysema**.
3. **Emphysema with irregular distribution**.

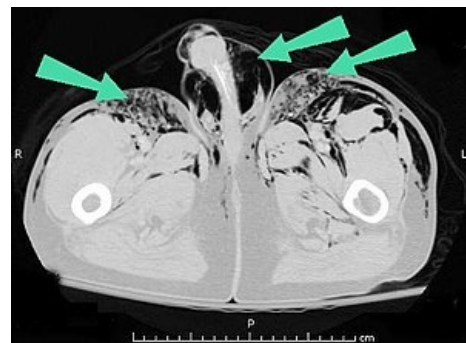
In all of these mentioned types, emphysema can be localized only in a certain segment of the lung or a lobe, but it can affect the entire lung.

The most clinically significant form of emphysema is the obstructive form (or centrilobular emphysema), the most common cause of which is chronic bronchitis . Genetically conditioned forms of emphysema are also known, when in the case of a congenital defect of $\alpha 1$ -antitrypsin the activity of proteolytic enzymes is not blocked (these are products of various bacteria, but also macrophages and neutrophils), which conditions the rapid development of destruction of the walls of both the bronchi and interalveolar septa. This genetically determined disease is characterized by the involvement not only of the lungs, but also of the liver parenchyma. If we have a younger individual in front of us, where in addition to the diagnosis of emphysema and liver cirrhosis a low fraction of alpha-1-globulin (less than 3%) dominates the biochemical analysis during electrophoresis of plasma proteins it is necessary to think about this disease. The diagnosis is then confirmed by the level of alpha-1-antitrypsin.

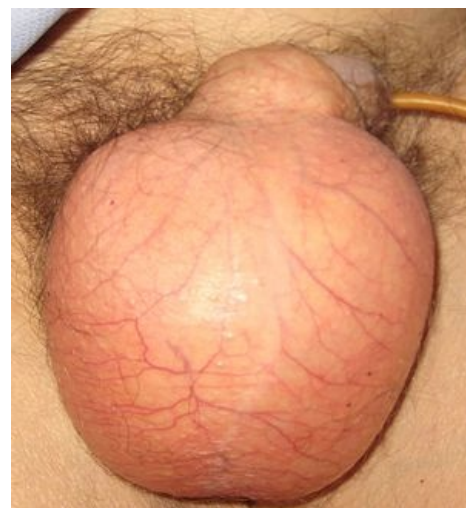Clinical picture of pulmonary emphysema

Cough and exertional dyspnea are considered typical symptoms of emphysema . During the examination, changes in the configuration of the chest are noticeable, such as the barrel-shaped chest, filled infraclavicular and supraclavicular pits, parallel course of the ribs, etc. In highly developed forms of pulmonary emphysema, earlier authors emphasized a simple sign that allowed the diagnosis at first glance in men: in emphysema there **is significantly shortened distance of the lower edge of the thyroid cartilage from the handle of the sternum, when cases of just a finger's width have even been described**.

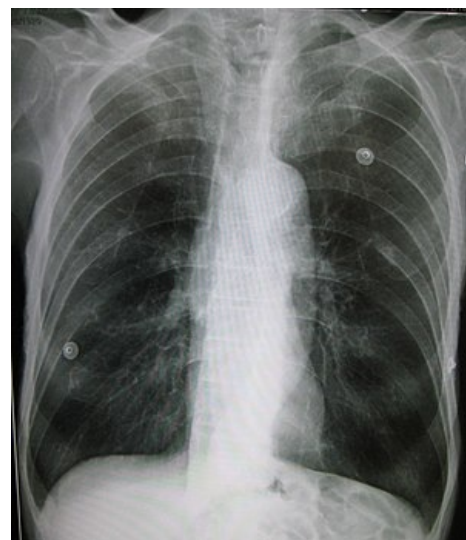In addition to changes in the configuration of the chest, when listening to the lungs, weakened breathing with significantly prolonged expiration, a low-lying and slightly mobile diaphragm, very quiet heart sounds can be heard.



Subcutaneous emphysema in the pelvis



Subcutaneous emphysema



Emphysema of the lungs



Centrilobular emphysema

- On **palpation**, there is classically a hypersonic chest-percussion as well as reduced absolute cardiac darkening, as the heart is covered by inflated lungs.
- Bright lung fields, flattened and low-lying domes of the diaphragm, almost horizontal ribs and a square chest are noticeable during X-ray examination.

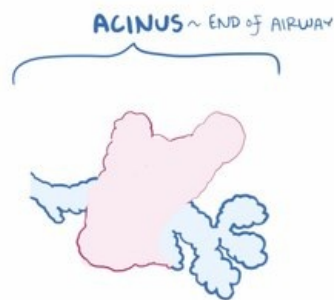However, all of the above-mentioned symptoms are only suitable for recognizing mostly advanced forms of emphysema, but they definitely do not allow for a diagnosis in the beginning or milder forms.

However, the interpretation of some of the symptoms was subject to considerable subjective evaluation (as an example we can cite weakened breathing). In chronic obstructive pulmonary disease (emphysema), in contrast to simple chronic inflammation of the bronchi, shortness of breath on exertion appears in addition to cough and expectoration.

Recently, two clinical types have been distinguished among patients

1. **Type A - emphysematic form** - patients have a large emphysematic chest, are usually asthenic, but marked shortness of breath is not accompanied by polyglobulia or cyanosis. Some authors refer to this type of patients as "pink puffers". Patients are short of breath but have pink skin.
2. **Type B - bronchial form** - these individuals are usually obese, bulbous protrusion dominates. Compared to type A, shortness of breath tends to be smaller, patients are cyanotic, tend to have polyglobulia and, unlike type A, they show signs of decompensated cor pulmonale. They are referred to as "blue bloaters" - the bloated, swollen, blue type.

In recent years, a special clinical form has been singled out, the so-called "small airway disease". It is an impairment of the peripheral airways. In these airways with a diameter of less than two millimeters, obstruction develops on the basis of congestion, mucostasis, fibrotization and collapse.



Video in English, definition, pathogenesis, symptoms, complications, treatment.

Therapy

A prerequisite for at least partially successful therapy is the exclusion of smoking, even passive smoking! It is necessary to adjust the microclimate - temperature, humidity, sufficient movement in healthy air, hardening, remediation of foci (paranasal sinuses) and breathing exercises are important.

For patients, the same principles apply as for simple chronic bronchitis - antitussives and expectorants are alternated (however, the effect is unconvincing, they are especially important in acute exacerbations, when antibiotics are also administered at the same time).

The main drugs are bronchodilators (before, ephedrine preparations were popular, now β 2 - sympathomimetics). In periods of deterioration, repeated inhalations are also suitable. Spa stays are indicated for patients with emphysema.

Links

related articles

- COPD
- Chronic bronchitis
- Bronchiectasis

References

- KORDAČ, Václav. *Internal medicine III*. 2. edition. Prague : Avicenum, 1991. ISBN 80-201-0187-X.
- HEGGLIN, Robert. *Differential diagnosis of internal diseases*. 1st Czech edition. Prague : Avicenum, 1972.

