

Congenital deformities of the auricle

Classification of the deformities according to Roger

- **mikrotia** (hypoplasia of auricle)
- **lop ear**
- **cup ear**
- **sticking out auricle (otapostasis)**

Classification according to Tanzer

- **Anotia** (complete absence of the auricle)
- **complete hypoplasia** (mikrotia) with / without outer ear canal atrophy
- **hypoplasia of middle 1/3 of the ear**
- **hypoplasia of upper 1/3 of the ear:** „constricted ear“ (overhanging earlobe + cone-shaped ear), cryptotia, hypoplasia of entire upper 1/3
- **sticking out auricle**

Other deformities

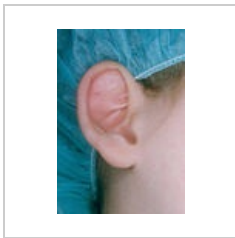
- **appendices praeauriculares** (rudimentary growths around the auricle)
- **fistulas** incomplete (leading to a short distance) / complete (leading up to the mouth or pharynx)

Associated disorders

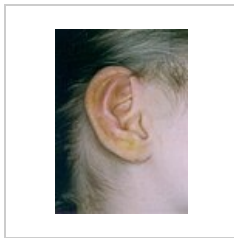
- **hearing disorders** based on middle ear anomalies, developmental disorders of the inner ear, hereditary disorders of cochlea development
- **hemifacial mikrosomia**
- **urinary tract anomalies**

Treatment

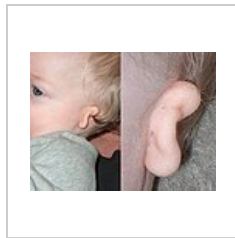
- surgery changing the shape of the cartilage of the pinna → soft tissue change
- most common are operations of sticking out auricles
- in case of non-development of the auricle we reconstruct the cartilage part with cartilage from the rib + soft tissues by tissue expansion and local shifts



Otapostasis



Antihelix after reconstruction



Mikrotia

Links

Related articles

- Congenital defects of the outer and middle ear
- Aquired defects of the auricle

Used literature

- MĚŠŤÁK, Jan, et al. *Úvod do plastické chirurgie*. 1. edition. Praha : Univerzita Karlova v Praze - Nakladatelství Karolinum, 2005. 125 pp. ISBN 80-246-1150-3.

