

Cone (C2) injury

We divide injuries of the second cervical vertebra into *dens axis* fractures and the so-called Katow's fracture. In the case of fractures of the dens, we distinguish (according to Alonso and Anderson):

- apex fractures (breaking off the top of the dens axis),
- dent body fractures,
- fractures of the base of the dent.

Fractures of this type occur during sudden flexion or extension of the head.

Hangman's fracture is named after the mechanism of the injury – it occurred during execution by hanging. In this fracture, the body of the axis breaks off from the vertebral arch, the fracture plane passes through the pedicles of the vertebra.

Clinical manifestations

Neurological deficit accompanies C2 fractures in about ten percent. A characteristic symptom is pain in the region of the cervical spine and in the occipital region. Most patients are also neurologically unaffected with a Cat's fracture, but in some cases, C2–C3 subluxation and cervical spinal cord injury may occur.

Diagnostics

- X-ray imaging in anteroposterior, lateral, transoral and dynamic projection;
- CT scan to detect fracture lines;
- MRI to assess the suspension apparatus.

Treatment

Treatment is based on whether the fracture is stable or not. We consider dent base fractures to be unstable, so they are indicated for surgical osteosynthesis. For the other two types, treatment is conservative, with immobilization in a *Philadelphia collar* for 10–12 weeks.

In the case of a Cat's fracture, the C2–C3 dislocation matters. A conservative approach can be taken if the C2–C3 dislocation is minimal, with immobilization in a cervical collar or halo-vest. We solve more significant dislocations surgically, here we perform a C2–C3 fusion with a plate.

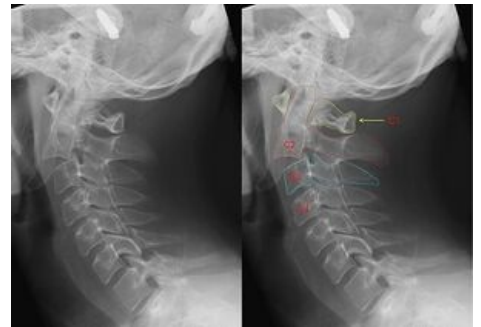
Links

Related articles

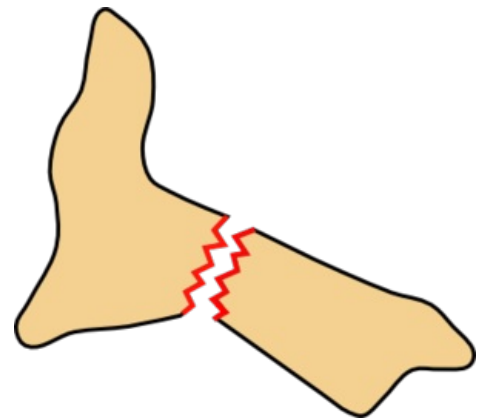
- Carrier Injury (C1)
- Vertebrae

References

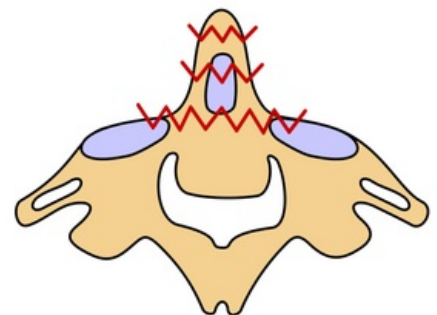
- KOUDELA, Karel, et al. *Ortopedická traumatologie*. 1. edition. Karolinum, 2002. pp. 147. ISBN 80-246-0392-6.
- SAMEŠ, Martin, et al. *Neurochirurgie : učebnice pro lékařské fakulty a postgraduální studium příbuzných oborů*. 1. edition. Praha : Jessenius Maxdorf, 2005. pp. 127. ISBN 80-7345-072-0.



Katow's fracture



Katow's fracture



C2 fractures

-
-
-
-