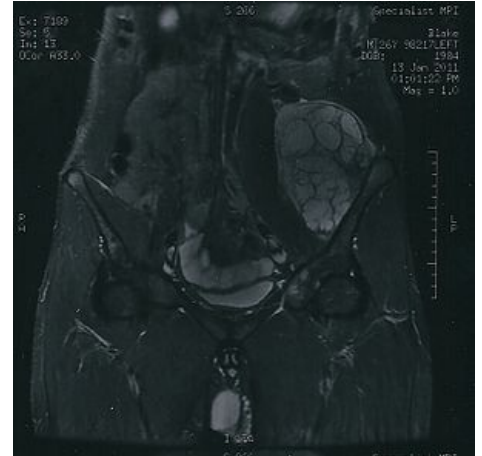

Chondrosarcoma

Chondrosarcoma is one of the most common malignant bone tumors, it is an adult tumor.

- In the metaphysis of the proximal part of the humerus, femur, tibia, , and elsewhere.
- It arises primarily or by malignancy of the enchondrum exostoses.
- Typically: a man aged 40-70 years, complains of pain in the gluteal region, the area of the hip joint or pain in the equilateral thigh / knee, attacks the affected limb, the pain gradually worsens and does not subside at rest.
- **X-ray:** intraosseous osteolytic lesion with islets calcification.
- **Histological picture:** lobularly arranged masses of cartilaginous tissue with cellular atypia.
- **Therapy::** single treatment surgical removal of the tumor: broad / radical resection of the tumor, ev. metastasectomy in solitary lung disease.



Left pelvic chondrosarcoma

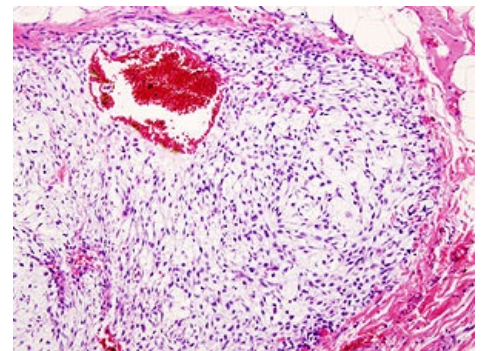
Links

Related articles

- Osteosarcoma
- Spinal tumors

References

- SOSNA, A. – VAVŘÍK, P. – KRBEC, M., et al. *Základy ortopedie*. 1. edition. Praha : Triton, 2001. ISBN 80-7254-202-8.
- GALLO, Jiří, et al. *Ortopedie pro studenty lékařských a zdravotnických fakult*. 1. edition. Olomouc : Univerzita Palackého v Olomouci, 2011. ISBN 978-80-244-2486-6.



Chondrosarcoma