

# Chalazion

This article has been translated from WikiSkripta; ready for the **editor's review**.

Template:Infobox - disease

**Chalazion** is an acute purulent inflammation Meibomian gland located in the area of the tarsal plate. Symptoms of inflammation are more pronounced than in barley grain - we observe redness, soreness and swelling with enlarged preauricular and submandibular nodes. The inflammation can progress to the formation of an abscess or phlegmon of the lid, or it turns into a chronic form.

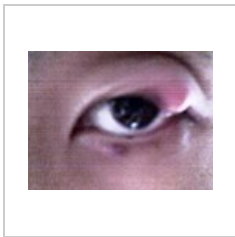
**Chronic chalazion** (*meibomian cyst*) is caused by a blockage of the mouth of the meibomian gland with accumulated secretion. The cyst is painless to palpation, we can see swelling in the tarsal plate of the eyelid. When the upper lid is everted, we see the conjunctiva arching through which a red-purple granuloma shines through, possibly. secondary infection.

## Therapy

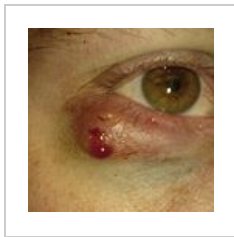
- We do not need to intervene if it does not cause cosmetic problems and it heals spontaneously.
- Injection of triamcinolone (0.1-0.2 ml) in combination with a local anesthetic into the swollen tissue.
- If the chalazion does not heal, we repeat the application after 2-3 weeks.
- Generally administered antibiotics for recurrences and especially in patients with acne rosacea or seborrhoeic dermatitis, in whom this disease is more common.
- Unsuccessful conservative therapy - under local anesthesia, an incision can be made perpendicular to the course of the lid and the contents of the chalazion excochleated.

## Differential diagnosis

A Meibomian gland tumor (rare) must be ruled out; if suspected, a biopsy with histology must be performed.



Chalazion of the upper lid



Bleeding chalazion of the lower eyelid

## Links

### Related Articles

- Inflammation of the eyelids
  - Meibomianitis
  - Blepharitis
  - Hordeolum

### References

■

” {{{1}}} “