

Category:Surgery

Subcategories

This category has the following 5 subcategories, out of 5 total.

N

- Neurosurgery (127 P, 2 F)

O

- Orthopedics (160 P)
- Otolaryngology (4 P)

T

- Traumatology (95 P, 2 F)

U

- Urology (109 P, 1 F)

Pages in category "Surgery"

The following 200 pages are in this category, out of 441 total.

(previous page) (next page)

A

- Abdominal aorta
- Abdominal Pain
- Abdominal pain (pathophysiology)
- Ablation
- Abscess
- Acetabulum fractures
- Acquired neck deformities (plastic surgery)
- Acute abdomen
- Acute abdomen in children
- Acute appendicitis
- Acute cholangitis
- Acute pancreatic necrosis
- Alloplasty
- Anal fistula
- Aneurysm
- Angioinvasive Treatment Arterial Occlusion and Stenosis
- Angioinvasive treatment of arterial blockages and stenoses
- Ankle fractures
- Anticancer therapy
- Antitumor therapy
- Aorta abdominalis
- Apoptosis signaling disorders in tumor cells
- Apostasis Auriculae
- Aquired defects of the auricle
- Arteria carotis externa
- Arterial reconstruction
- Arterial Reconstruction
- Arteries of the lower limbs
- Arteriovenous fistula
- Artery cannulation
- Artery reconstruction
- Arthroplasty
- Arthroscopy
- Arthrotomy
- Asepsis
- Atlas injury (C1)
- Atrial septal defect
- Atypical facial clefts

- Axis injury

B

- Bandages
- Bariatric surgical procedures
- Barrett's Esophagus
- Basilic hiatus
- Benign
- Berry's Ligament
- Bile duct tumors
- Biliary tract
- Biological properties of tumors
- Biology of oncogenesis
- Bladder and urethral injuries
- Blast Syndrome
- Bleeding
- Bleeding from the alimentary canal
- Blockage of Large Veins
- Blunt injuries to internal organs
- Both bone forearm fractures
- Bowel malrotation and volvulus
- Talk:Brain edema
- Brain edema
- Burn necrosis
- Bypass

C

- Calculi
- Calot's Triangle
- Capillary return test
- Carcinogens
- Carcinoma
- Cardiac tamponade
- Cardioplegia
- Carotid endarterectomy
- Carrier Injury (C1)
- Causes of Abdominal Pain
- Cavernous sinus
- Cerclage
- Cervical plexus
- Characteristics of tumour growth
- Cheilotomy
- Cholecystectomy
- Chronic ischemic disease of the lower limbs
- Chronic Pancreatitis
- Chronic venous insufficiency
- Circle of Willis
- Clavicle fractures
- Coarctation of the aorta
- Cold injury
- Colic
- Colles Fracture
- Colorectal cancer
- Colorectal cancer/PGS
- Colorectal cancer/screening
- Colorectal cancer/staging
- Colorectal cancer/therapy
- Colorectal carcinoma
- Colorectal carcinoma (PGS)
- Colorectal carcinoma/diagnosis
- Colorectal carcinoma/epidemiology
- Colorectal carcinoma/screening
- Colorectal carcinoma/staging
- Compartment syndrome
- Compartment syndrome of the lower leg
- Complications in the surgical wound
- Complications of diabetes mellitus
- Complications of gastric and duodenal ulcers
- Compound fractures of the radius and the ulna
- Concretions
- Concussion
- Cone (C2) injury
- Congenita muscularis torticollis

- Congenital defects of the gastrointestinal tract
- Congenital deformities of the auricle
- Congenital deformities of the neck
- Congenital developmental defects of the newborn requiring an urgent solution
- Congenital diaphragmatic hernia
- Congenital Heart Defects
- Congenital malformations of the auricle
- Congenital malformations of the respiratory system
- Congenital Megacolon
- Coniotomy
- Courvoisier's Sign
- Craniocerebral trauma
- WikiLectures talk:Create new article
- Crush syndrome
- Cytoreductive surgery

D

- Damage control surgery
- Decubitus
- *Defense musculaire*
- Dermoidy
- Diagnostic imaging methods in sudden abdominal events
- Diaphragmatic hernia
- Differential diagnosis of inflammatory and ileal acute abdomen
- Disinfection and sterilization
- Dislocation of Shoulder Joint
- Dislocation of the elbow joint
- Dislocation of the shoulder joint
- Disorders of apoptosis signaling in tumor cells
- Disorders of hemostasis
- Dissection
- Dissection of the thoracic aorta
- Distant flaps
- Distortion
- Diverticular Disease
- Documentation in surgery
- Drop test
- Dupuytren's contracture
- Dyspepsia

E

- Ear Injury
- Early infections
- Ebstein anomaly
- Edmonton protocol
- Elbow joint luxation
- Empyema
- Endoscopy in Plastic Surgery
- Epidural hematoma
- Epidural Hematoma
- Ergotherapy
- Errors and mistakes in the diagnosis of sudden abdominal attack
- Esophagus
- Examination per rectum
- Exarticulation
- Extent of burn injury
- External carotid artery
- Extra-intracranial anastomosis

F

- Facial reconstruction
- Facial soft tissue injuries
- Fractures of the proximal femur
- Familial adenomatous polyposis
- Fascial excision
- Femoral hernia
- First Aid
- First aid for chest injuries
- Focal Infection
- Follicular cyst of the maxilla and mandible - case report
- Foramen omentale
- Forearm fractures

- Forearm fractures
- Fracture healing disorders
- Fractures of clavicle
- Fractures of lower leg
- Fractures of the bones of the leg
- Fractures of the diaphysis of the femur
- Fractures of the diaphysis of the humerus
- Fractures of the diaphysis of the radius and ulna
- Fractures of the distal end of the humerus
- Fractures of the distal radius
- Fractures of the facial skeleton
- Fractures of the femoral diaphysis
- Fractures of the humerus
- Fractures of the kneecap
- Fractures of the leg bones
- Fractures of the lower end of the femur
- Fractures of the lower leg
- Fractures of the proximal femur
- Fractures of the proximal radius
- Fractures of the proximal ulna
- Fractures of the scapula
- Fractures of the tibia

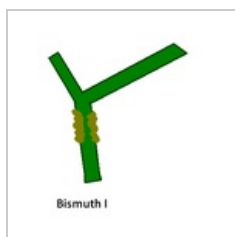
G

- Galeazzi fracture
- Gallbladder
- Ganglion
- Gastrointestinal Haemorrhage
- General anesthesia
- General principles of anticancer treatment

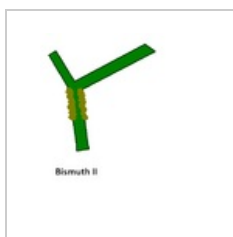
(previous page) (next page)

Media in category "Surgery"

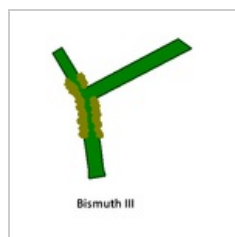
The following 9 files are in this category, out of 9 total.



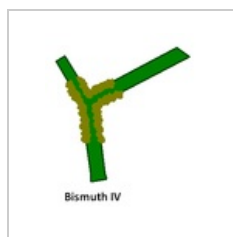
Bismuth I.PNG
320 × 343; 5 KB



Bismuth II.PNG
398 × 446; 7 KB



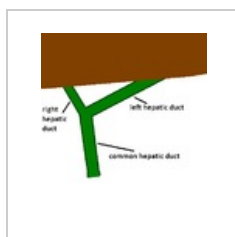
Bismuth III.PNG
296 × 341; 5 KB



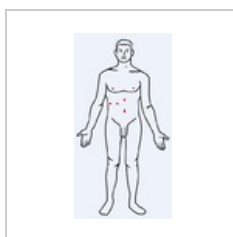
Bismuth IV.PNG
302 × 355; 6 KB



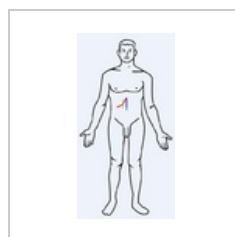
Chirurg.png
50 × 50; 4 KB



Hepatiky s játry....
398 × 446; 8 KB



Laparoskopie.PNG
331 × 630; 35 KB



LaparotomieCHC...
331 × 630; 35 KB



Surgery.jpg
400 × 400; 69 KB