

Category:Gastroenterology

Pages in category "Gastroenterology"

The following 200 pages are in this category, out of 248 total.

(previous page) (next page)

1

- 13C-mixed triacylglyceride breath test

A

- Abdominal Pain
- Abdominal Pain in Children (Paediatrics)
- Abdominal puncture (paediatrics)
- Acute cholangitis
- Acute pancreatic necrosis
- Acute pancreatitis (diagnostic tests)
- Acute Phase Reactants
- Administration of nutrition and drugs via percutaneous endoscopic gastrostomy
- AMA
- Amylase
- Anal fistula
- Antacids
- Antispasmodics
- Ascites
- Autoimmune pancreatitis

B

- Bacterial Gastroenteritis
- Barrett's Esophagus
- Bile
- Bile duct tumors
- Biliary tract
- Biochemical examination of the pancreas
- Bleeding from the alimentary canal
- Bowel emptying disorders
- Bowel malrotation and volvulus
- Breath tests (signpost)
- Budd - Chiari syndrome
- Budd-Chiari Syndrome

C

- Calculi
- Calprotectin in faeces
- Campylobacter Enteritis
- Campylobacter enteritis 1.If
- Carbohydrate coefficient transferrin
- Carbohydrate deficient transferrin
- Carbon-13 labeled D-xylose breath test
- Carcinoma of Papilla Vateri
- Causes of Abdominal Pain
- Cavocaval anastomosis
- Celiac disease screening
- Cholecystectomy
- Chronic eating disorders
- Chronic Pancreatitis
- Coeliac Ganglion Blocade
- Colon polyps
- Colonoscopic examination
- Colorectal adenoma
- Colorectal cancer
- Colorectal cancer/pathology
- Colorectal cancer/PGS
- Colorectal cancer/prognosis
- Colorectal cancer/screening

- Colorectal cancer/staging
- Colorectal cancer/symptomatology
- Colorectal cancer/therapy
- Colorectal carcinoma
- Colorectal carcinoma (PGS)
- Colorectal carcinoma/diagnosis
- Colorectal carcinoma/epidemiology
- Colorectal carcinoma/etiology
- Colorectal carcinoma/prognosis
- Colorectal carcinoma/screening
- Colorectal carcinoma/staging
- Complications of gastric and duodenal ulcers
- Concretions
- Congenital defects of the gastrointestinal tract
- Congenital Megacolon
- Courvoisier's Sign
- Crigler-Najjar syndrome
- Cystic fibrosis

D

- Dermatitis herpetiformis
- Detection of antibodies against *Helicobacter pylori*
- Determination of antibodies against *Helicobacter pylori*
- Development of the duodenum
- Diagnosis of *Helicobacter Pylori* Infection
- Diagnostic imaging methods in the examination of the digestive tract
- Diagnostic imaging methods in the examination of the gallbladder and bile ducts
- Diagnostic use of ultrasound
- Diarrhea (pediatrics)
- Diarrheal diseases (guide)
- Diarrheal diseases (signpost)
- Diet in diseases of the pancreas and gallbladder
- Differential diagnosis of chest pain/PGS (VPL)
- Differential diagnosis of diarrheal diseases
- Differential diagnosis of diarrhoeal diseases
- Differential diagnosis of inflammatory and ileal acute abdomen
- Differential diagnosis of swallowing disorders
- Diffuse Esophageal Spasm
- Digestion
- Digestion of lipids
- Diseases of the salivary glands
- Diverticular Disease
- DNA isolation and genetic markers
- Dyspepsia

E

- Endoscope
- Enteral nutrition in oncological diseases of the GIT
- Enteroscopy
- Enterotoxigenesis
- Eradication of *Helicobacter pylori*
- Esophageal disease
- Esophageal Varices
- Esophagus
- Examination of the digestive tract
- Examination per rectum
- Extracorporeal shock wave lithotripsy

F

- Fecal Occult Blood Test (FOBT)

G

- Gallbladder
- Gallbladder cancer
- Gastric acid
- Gastric juice
- Gastrin
- Gastrinoma
- Gastroduodenal ulcer disease
- Portal:Gastroenterology

- Gastroesophageal reflux
- Gastrointestinal Haemorrhage
- Gastrointestinal stromal tumor/PGS
- Gastroscopy
- General structure of the alimentary canal

H

- Hemochromatosis
- Hepatic Encephalopathy
- Hepatic encephalopathy
- Hepatic Failure
- Hepatite A
- Hepatitis
- Hepatitis A
- Hepatitis B
- Hepatitis C
- Hepatomegaly
- Hepatoprotective
- Hepatoprotectors
- Hepatorenal Syndrome
- Hiatal hernia

I

- Immunochemical test for blood in feces
- Inflammation of the stomach
- Inflammatory diseases of the gallbladder and bile ducts
- Intestinal malrotation and volvulus
- Intestinal permeability lactulose/mannitol test
- Intestine (signpost)

K

- Klatskin Tumor

L

- Portal: Laboratory tests and methods in Gastroenterology
- Lactose tolerance test
- Ladd's syndrome
- Laxatives
- Linitis plastica
- Lipase
- Lipase as a macroenzyme
- Lipase/Assessment
- Liver cirrhosis
- Liver Cysts and abscess
- Liver tumors

M

- Malabsorption syndrome
- Mallory-Weiss syndrome (password)
- Malrotation of volvulus and intestines
- Measurement of gastric acid secretion
- Meckel's Diverticulum
- Megacolon congenitum
- Miserere
- Monitoring of the internal environment in intensive care

N

- Non-alcoholic steatohepatitis
- Non-celiac gluten sensitivity
- Non-infectious chronic liver diseases
- Non-specific intestinal inflammations

O

- Obesity (pediatrics)
- Oesophageal tumors

P

- Painful syndrome of the left lower abdomen
- Painful syndrome of the right lower abdomen
- Painful syndrome of the upper abdomen
- Pancreas divisum
- Pancreas Transplantation
- Pancreatic Cancer
- Pancreatic carcinoma
- Pancreatic elastase
- Pancreatic steatosis
- Pancreatitis (signpost)
- Paracentesis (gastroenterology)
- Pathology of gastric adenocarcinoma
- PEG
- Pepsin
- Peptic Ulcer Treatment
- Periproctal fistula
- Peutz-Jeghers syndrome
- Pharmacotherapy of Helicobacter pylori
- Plasma proteins
- Polyps of the large intestine
- Portal Hypertension
- Postoperative gastrointestinal complications
- Primary biliary cholangitis
- Primary sclerosing cholangitis
- Procalcitonin
- Proteins in serum and urine (1. LF UK, VL)

Q

- Portal:Questions for final examination in Internal Medicine (1. LF UK, GM)
- Portal:Questions for final examination in Internal Medicine/Gastroenterology (1. LF UK, GM)

R

- Radiodiagnostic examination of the colon
- Radiodiagnostic examination of the esophagus and stomach
- Radiodiagnostic examination of the esophagus and the stomach
- Radiodiagnostic examination of the large intestine
- Radiodiagnostic examination of the small intestine
- Reflux disease of the esophagus

S

- Salivary gland diseases
- Salmonellosis

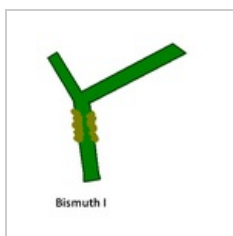
(previous page) (next page)

Media in category "Gastroenterology"


The following 12 files are in this category, out of 12 total.



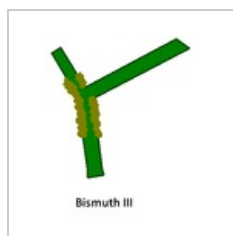
Aktivační kaskád...
720 × 540; 57 KB



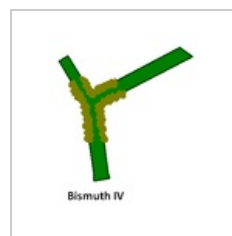
Bismuth I.PNG
320 × 343; 5 KB



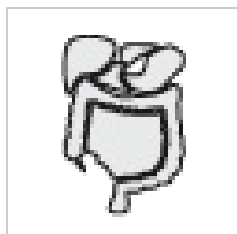Bismuth II.PNG
398 × 446; 7 KB




Bismuth III.PNG
296 × 341; 5 KB



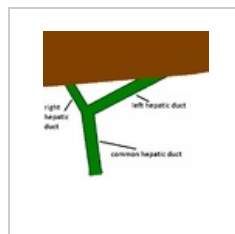
Bismuth IV.PNG
302 × 355; 6 KB



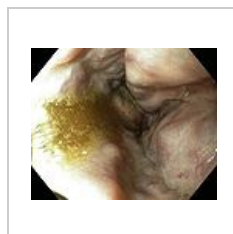
Gastro.png
50 × 50; 5 KB



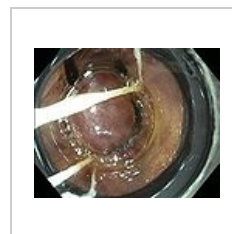
Gastroenterologi...
423 × 423; 74 KB



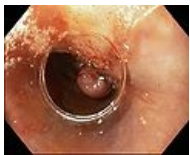Hepatiky s játry...
398 × 446; 8 KB



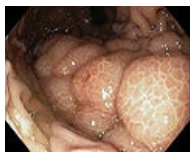Ligace2.JPG
643 × 527; 39 KB



Ligace3.JPG
645 × 524; 53 KB



Ligace5.JPG
644 × 523; 45 KB



Žal-varixy.jpg
510 × 400; 170 KB